

**12****AUTOPSY REPORT**

No. 2020-00803

ZOBAYAN, ARA

I performed an autopsy on the body of →

at \_\_\_\_\_  
the DEPARTMENT OF MEDICAL EXAMINER-CORONER

Los Angeles, California

on January 28, 2020

1000

(Date)

(Time)

From the anatomic findings and pertinent history I ascribe the death to:

(A) Blunt trauma

DUE TO OR AS A CONSEQUENCE OF

(B)

DUE TO OR AS A CONSEQUENCE OF

(C)

DUE TO OR AS A CONSEQUENCE OF

(D)

OTHER CONDITIONS CONTRIBUTING BUT NOT RELATED TO THE IMMEDIATE CAUSE OF DEATH

MANNER OF DEATH

Accident

HOW INJURY OCCURRED

Commercial helicopter crash (pilot)

**Anatomic Summary:**

## I. Extensive blunt force injuries

A. Multiple fractures of the skull, spine, torso and extremities

B. Evisceration of the cranium and abdomen

C. Lacerations of the internal organs and major vessels

## II. No soot deposition within the airway

**CIRCUMSTANCES:**

This 50 year old male was reported as a John Doe following a commercial helicopter crash with multiple passengers. He was determined to be the pilot and was identified by fingerprints. Please see Coroner Investigator's report for further details.

**EXTERNAL EXAMINATION:**

The body is identified by toe tags bearing the case number and name of the decedent. The body is that of an unembalmed refrigerated adult male who has extensive blunt force traumatic injuries. The body weighs 140 pounds at the time of autopsy. The body habitus does not appear overweight. Examination of the skin shows no evidence of jaundice. No prominent or unique scars are identified. No tattoos are identified.

The majority of the head, excluding portions of occipital bone, mandible, scalp and ears is absent. The scalp hair is gray-

# AUTOPSY REPORT

DEPARTMENT OF MEDICAL EXAMINER-CORONER

No. 2020-00803

ZOBAYAN, ARA

**12**Page 3**D. Upper extremities**

1. Multiple gaping lacerations, proximal and distal, bilateral
2. Multiple displaced fractures, proximal and distal, bilateral

**E. Lower extremities**

1. Complete dermal avulsion of the lower extremities from hip to ankle bilaterally
2. Multiple displaced fractures, proximal and distal, bilateral

**NECK:**

The neck organs are removed and opened. There is no soot in the pharynx, larynx or trachea. There is no edema of the larynx or epiglottis. There is scattered hemorrhage around the investing fascia, strap muscles and surface of the thyroid gland. There are prevertebral fascial hemorrhages of the cervical spine.

**CHEST/ABDOMINAL CAVITY:**

There is scant blood within the chest cavity. The organs of the abdomen and pelvis have been eviscerated and show disrupted organization.

**SYSTEMIC AND ORGAN REVIEW:**

*Note: The following observations are limited to findings other than described above.*

**MUSCULOSKELETAL SYSTEM:**

No abnormalities of the uninjured bony framework or muscles are identified.

**CARDIOVASCULAR SYSTEM:**

The thoracic and abdominal aorta have minimal atherosclerosis. The pericardial sac is not intact.

The heart tissue weighs 200 grams. The configuration is disrupted, and the anatomic landmarks are not well preserved. The left ventricle is approximately 1.0 cm in thickness. Discernible portions of the cardiac valves show no vegetations.

# AUTOPSY REPORT

DEPARTMENT OF MEDICAL EXAMINER-CORONER

No. 2020-00803

ZOBAYAN, ARA

**2**

brown, straight, and up to approximately 1 ½ inches in length. There is some balding over the vertex of the scalp. The facial hair appears to be recently shaven and is gray brown in color. The facial structures have been completely disrupted. A portion of mandible containing two molars, one of which has a metallic filling, is identified. The tongue is fragmented. The eyes are not identified.

There is visible and palpable chest deformity. There is abdominal and pelvic evisceration. The penis is present within the abdominal and pelvic contents. All extremities show extensive blunt trauma with multiple deformities. Both hands are present and articulate with the upper extremities. Both feet are present and are attached to the lower extremities via skin and soft tissue. The fingernails and toenails are neatly trimmed and without overhang. Rigor mortis is not appreciated. There is faint livor mortis present over the posterior torso.

**EVIDENCE OF THERAPEUTIC INTERVENTION:**

There is no evidence of medical intervention.

**EVIDENCE OF INJURY:**

## Blunt force trauma

## A. Head and neck

1. Extensive comminuted fractures of the occipital bones with scalp avulsion
2. Complete disruption of the facial structures
3. Displaced fracture of the cervical spine

## B. Thorax

1. Numerous comminuted anterior and posterior rib fractures
2. Multiple lacerations of the heart, great vessels, lungs and diaphragm
3. Displaced fracture of the thoracic spine
4. Scattered perimortem abrasions of the back

## C. Abdomen and pelvis

1. Abdominal-pelvic evisceration
2. Numerous lacerations of the liver, spleen and left kidney
3. Multiple displaced fractures of the sacrum

20

2020-00803

Zobayan, Ara

Abdominal  
evisceration  
w/ pelvic fractures  
and dirt/debris  
scattered throughout  
tissues.

laceration

gray brown hairy chest/shoulders/arms  
w/ scattered contusion  
and chest collapse

Scattered  
post-mortem  
abrasion  
over back

laceration  
w/ humeral shaft

extensive  
rib fractures

laceration  
w/ open  
displaced  
fracture

laceration  
w/ fracture  
2020-00803

All fingers  
and thumb  
present, scattered  
lacerations  
and fractures

All fingers  
and thumb present  
trimmed well groomed  
details, no overhang

Back skin  
from neck to  
buttocks mostly  
intact. No deep  
soft tissue.

deep soft-tissue  
exposure of L. leg  
from hip to ankle  
disarticulation @ knee  
femur, tib fib fractures

Midshaft  
Open femur  
fracture.  
Deep soft tissue  
exposure of  
Right leg from  
hip to ankle.

Foot attached by  
soft-tissue/skin  
all toes present

lacerations

All toes  
present

Nails clean  
well groomed  
No overhang

Multiple tib/fib  
fractures, open.  
Foot attached by  
skin/soft tissue

laceration  
w/ underlying  
fracture

Date 1-28-2020

Deputy Medical Examiner

M.D.

2

# AUTOPSY REPORT

DEPARTMENT OF MEDICAL EXAMINER-CORONER

No. 2020-00803


ZOBAYAN, ARA

Microscopic examination of the heart showed mild fibrosis within the myocardium.

Toxicological testing did not detect the presence of alcohol or drugs of abuse. Substances tested for include: benzodiazepines, cocaine, fentanyl, heroin, marijuana, opioids, phencyclidine and amphetamines. Blood carboxyhemoglobin testing revealed less than 10% saturation.

The blunt force traumatic injuries sustained are considered rapidly fatal. The absence of an elevated carboxyhemoglobin level in the blood, in addition to the absence of soot in the airways, indicates that smoke inhalation did not occur.


The cause of death is blunt trauma sustained during a commercial helicopter crash. The manner of death is accident.



4-28-2020

Bruce L. Hunt, M.D.  
Associate Deputy Medical Examiner

Date



4-28-2020

Jonathan Lucas, M.D.  
Chief Medical Examiner-Coroner

Date

# AUTOPSY REPORT

DEPARTMENT OF MEDICAL EXAMINER-CORONER

**12**

No. 2020-00803

ZOBAYAN, ARA

Page 5

**GENITAL SYSTEM:**

The prostate is not enlarged and is without nodularity. The testes are not identified.

**HEMOLYMPHATIC SYSTEM:**

The spleen is 40 grams. The capsule is disrupted. The parenchyma is dark red and soft. The bone marrow of the rib is unremarkable.

**ENDOCRINE SYSTEM:**

The thyroid parenchyma and right adrenal gland are unremarkable. The parathyroid glands are not individually dissected. The thymus is not grossly identified.

**HEAD AND CENTRAL NERVOUS SYSTEM:**

There are fragmented portions of occipital bone identified. The facial bones and majority of the calvarium are unidentifiable. There is no identifiable brain tissue or dura.

**SPINAL CORD:**

Segments of cervical and thoracic spinal cord are removed. There is a transecting defect near the cervical thoracic junction.

**EVIDENCE COLLECTION:**

Multiple fragments of metal and plastic were present throughout the tissues of the head, extremities and torso. These were collected, placed in a labeled container and turned over to the supervising forensic technician.

**RETAINED TISSUE:**

Representative sections from various organs are preserved in one storage jar.

**HISTOLOGIC KEY:**

A1 - Liver and left ventricle of heart.

**TOXICOLOGY:**

Samples of chest blood, bile, liver and gastric contents are submitted to the laboratory. An EDTA tube containing chest blood and skeletal muscle were collected for typing. Samples of bile, blood (cavity), gastric contents, heart, kidney, liver,

**AUTOPSY REPORT**

DEPARTMENT OF MEDICAL EXAMINER-CORONER

No. 2020-00803

ZOBAYAN, ARA

**12**Page 4

The coronary ostia are patent, located at or below the sinotubular junction and are relatively centrally located within their respective sinuses. The coronary arteries are poorly preserved, but atherosclerosis is not appreciated. No pallor, softening, or fibrosis is present within the myocardium.

**RESPIRATORY SYSTEM:**

Scant secretions are found in the upper respiratory and lower bronchial passages. No soot is present within the bronchi. The mucosa is intact and pale. The right lung is 375 grams and the left lung is 350 grams. The pulmonary parenchyma is dark red-purple and the cut surfaces exude a scant amount of blood and serous fluid. The pulmonary vasculature is without thromboembolism.

**GASTROINTESTINAL SYSTEM:**

No esophageal varices are present. The stomach contains approximately 5 cc of tan-brown liquid. The mucosa is unremarkable. The small intestine and colon are unremarkable. The appendix is present and unremarkable. The pancreas occupies a normal position. There is no necrosis, fibrosis or hemorrhage within the parenchyma.

**HEPATOBIILIARY SYSTEM:**

The liver tissue is coarsely fragmented, weighs 850 grams, and is red-brown. The parenchyma is soft and friable. The cut surface is hemorrhagic. There is no evidence of nodular cirrhosis. The gallbladder is present. The wall is thin and pliable. It contains a moderate amount of bile and no calculi.

**URINARY SYSTEM:**

The right kidney is 175 grams, and the left kidney is 140 grams. The kidneys are situated within the abdomen. The capsule of the right kidney strips easily revealing a surface that shows normal smooth glistening cortex and a single simple cortical cyst measuring 1 cm in greatest dimension. The left kidney is partially disrupted. The corticomedullary demarcation of the renal parenchyma is preserved. The pyramids are unremarkable. The urinary bladder is lacerated and has exposed unremarkable mucosa. It contains no urine.

**AUTOPSY REPORT**

DEPARTMENT OF MEDICAL EXAMINER-CORONER

No. 2020-00803

ZOBAYAN, ARA

**12**

Page 6

lung, muscle and spleen were submitted to the Federal Aviation Administration.

**PHOTOGRAPHY:**

Photographs were taken prior to and during the course of the autopsy.

**CLOTHING:**

The clothing was examined and consisted of a fragmented black leather belt, a black jacket with a logo reading "AS350 trained", a black Northface brand zip up jacket, dark colored Kuhl brand pants, and Gilden brand black briefs and white undershirt. Fragments of metal buckle and electronic circuitry were scattered amongst the clothes. The clothes were tattered, blood stained, wet and smelled of fuel.

**RADIOLOGY:**

A postmortem computed tomography scan and 25 radiographs were obtained. They show numerous fractures of all four extremities, the spinal column, pelvis, clavicles, cranium and scapula.

**WITNESSES:**

No outside personnel were present to witness the autopsy.

**DIAGRAMS USED:**

Diagram form #20 and 22 were used during the performance of the autopsy. Coroner diagrams are not intended to be facsimiles nor are they drawn to scale.

**SUMMARY & OPINION:**

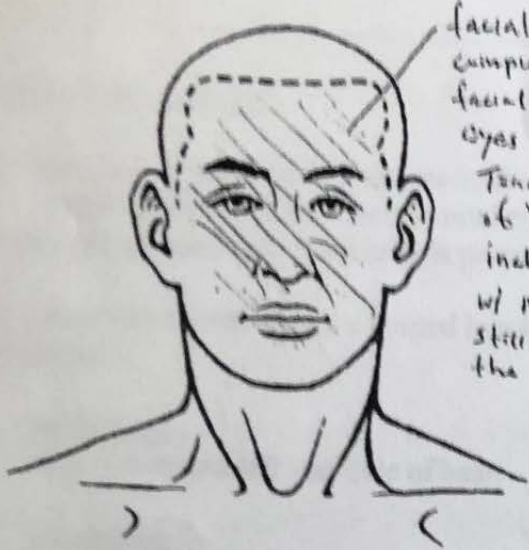
This 50 year old male was initially reported as a John Doe following a commercial helicopter crash involving a total of eight other passengers on 1/26/2020. He was identified as Ara Zobayan by fingerprint comparison on 1/27/2020. He was determined to be the pilot of the helicopter based on his clothing, restraint harness, and proximity to the pilots chair at the scene.

Autopsy revealed extensive blunt force traumatic injuries including multiple fractures of the skull and spine in addition to multiple internal organ lacerations.

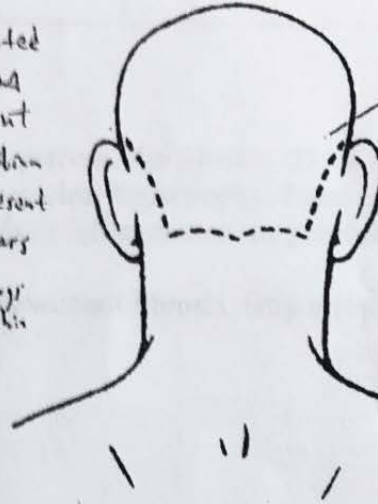
22

2020-00853

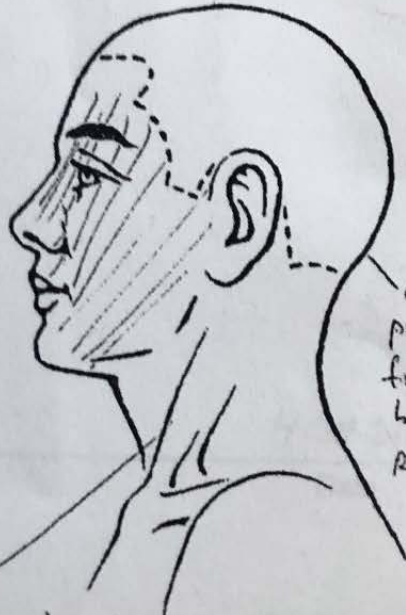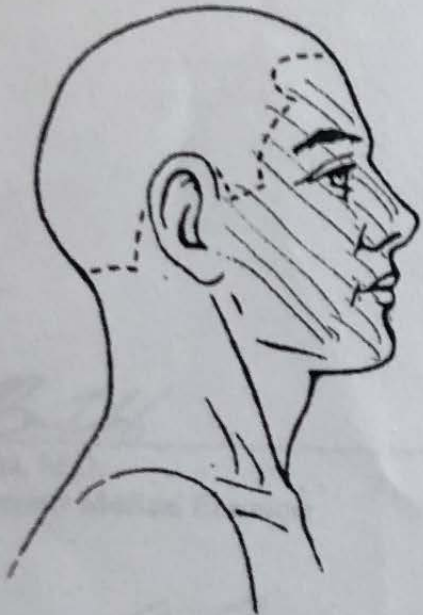Zobayan, Ara



facial anatomy completely disrupted  
 facial bones absent  
 eyes absent. scant  
 Tongue and portion  
 of mandible present  
 including 2 molars  
 w/ metallic fillings  
 still present within  
 the bone.



Scalp present.  
 Vertex balding  
 Straight gray -  
 brown hair  
 ~1 1/2 inch in  
 length. Ears  
 present. Remaining  
 facial skin around  
 ear shows recently  
 shaved gray stubble  
 hair



occipital bones  
 present, numerous  
 fragments held  
 by posterior scalp.  
 remainder of  
 cranium absent

vessels of neck  
 and trachea exposed.

Date 1-28-2020

*[Handwritten Signature]*

Deputy Medical Examiner

M.D.

16

2020-00803

DOE, JOHN

ACCIDENT

25

EXTERNAL EXAM

Sex Male  
 Race Caucasian  
 Age 50  
 Height  
 Weight 140 lbs  
 Hair gray brown  
 Eyes absent  
 Sclera  
 Teeth 2 teeth recovered without mandible  
 Mouth  
 Tongue  
 Nose  
 Chest  
 Breasts  
 Abdomen  
 Scar  
 Genitals  
 Edema  
 Skin  
 Decubitus  
**HEART Wt.** 200  
 Pericardium  
 Hypertrophy  
 Dilation  
 Muscle  
 Valves  
 Coronaries

RV  
 Septum  
 LV ~ 1.0 cm  
 Septum

AORTA  
VESSELS

**LUNGS Wt.**  
 R 375  
 L 350  
 Adhesions  
 Fluid  
 Atelectasis  
 Oedema  
 Congestion  
 Consolidation  
 Bronchi  
 Nodes

PHARYNX  
TRACHEA  
THYROID

THYMUS  
LARYNX ✓ No soub in airway

HYOID  
ABDOMINAL WALL FAT

PERITONEUM

Fluid  
 Adhesions  
**LIVER Wt.** 350  
 Capsule  
 Lobules  
 Fibros  
 GB present  
 Gallbladder  
 Bile ducts  
**SPLEEN Wt.** 40g  
 Color  
 Consistency  
 Capsule  
 Malpiment  
**PANCREAS** ✓  
**ADRENALS** Right adrenal present  
**KIDNEYS Wt.**  
 R 175  
 L 140  
 Capsule Simple cortical  
 Cortex Cyst on R. kidney  
 Vessels  
 Pelvis  
 Ureters

BLADDER  
GENITALIA

Prostate Penis present and attached  
 Testes Testes not identified  
 Uterus  
 Tubes  
 Ovaries

OESOPHAGUS

**STOMACH** Contents ~ 5cc

**DUOD. & SM. INT.**  
**APPENDIX** present

**LARGE INT.**  
**ABDOM. NODES**

**SKELETON** displaced  
 Spine Fractures of  
 Marrow cervical spine  
 Rib Cage thoracic spine  
 Long bones and sacrum  
 Pelvis

SCALP

**CALVARIUM**  
**BRAIN Wt.** Not present  
 Dura Not present  
 Fluid  
 Ventricles  
 Vessels  
 Middle ears  
 Other  
**PITUITARY** Not present

SPINAL CORD

**TOXICOLOGY SPECIMENS**  
Chest blood, bile, gastric, liver

**SECTIONS FOR HISTOPATHOLOGY**  
1. Liver and LV

MICROBIOLOGY

**DIAGRAMS**  
**X-RAYS**

**OTHER PROCEDURES**  
Federal Aviation Admin  
Tox box kit collected

GROSS IMPRESSIONS

Date 1-28-2020

Time 10:00 - 2:30

Deputy Medical Examiner

B. J. H. [Signature]



14

I performed a microscopic examination on  
2/10/2020



NO. 2020-00803

at THE DEPARTMENT OF CORONER

ZOBAYAN, ARA

Los Angeles, California

Microscopic description:

Heart: A section of left ventricle shows mild interstitial and perivascular fibrosis. There is a minute focus of replacement fibrosis. There is mild myocardiocyte nuclear hypertrophy. Focal perivascular extravasation of intact red blood cells is present. No necrosis or inflammation are present.

Liver: A section of liver shows a normal lobular architecture without fibrosis, fatty metamorphosis or inflammation.

Slide Key:

A1 - Liver and left ventricle of heart

Diagnosis:

1. Heart with mild interstitial fibrosis
2. Liver with no histopathologic changes

Brice L. Hunt, M.D.  
Associate Deputy Medical Examiner

4-28-2020

Date

Jonathan Lucas, M.D.  
Chief Medical Examiner-Coroner

4-28-2020

Date



Department of Medical Examiner-Coroner, County of Los Angeles

# FORENSIC SCIENCE LABORATORIES

1104 North Mission Road, Los Angeles, CA 90033



## Laboratory Analysis Summary Report

Lucas, Jonathan M.D.

Deputy Medical Examiner  
1104 North Mission Road  
Los Angeles, CA 90033

PendingTox

**Coroner Case Number:** 2020-00803 **Decedent:** ZOBAYAN, ARA

<u>SPECIMEN</u>	<u>SERVICE</u>	<u>DRUG</u>	<u>RESULT</u>	<u>ANALYST</u>
-----------------	----------------	-------------	---------------	----------------

### Alcohol Quantitation/Confirmation

EDTA Chest Blood

Alcohol-GC/FID-HS	Ethanol	* Negative	C. Castellino
-------------------	---------	------------	---------------

### Drug Screen

EDTA Chest Blood

ELISA-Immunoassay	Benzodiazepines	ND	J. Posada
ELISA-Immunoassay	Cocaine and Metabolites	ND	J. Posada
ELISA-Immunoassay	Fentanyl	ND	J. Posada
ELISA-Immunoassay	Marijuana:11-nor-Delta-9-Carboxy-THC	ND	J. Posada
ELISA-Immunoassay	Methamphetamine & MDMA	PP	J. Posada
ELISA-Immunoassay	Opiates: Codeine & Morphine	ND	J. Posada
ELISA-Immunoassay	Opiates: Hydrocodone & Hydromorphone	ND	J. Posada
ELISA-Immunoassay	Phencyclidine	ND	J. Posada

### Drug Screen/Confirmation

EDTA Chest Blood

Carbon Monoxide-CO-Ox	Carboxyhemoglobin	< 10 % Saturation	I. Lee
Sympath. Amines-GC/MS	Sympathomimetic Amines	** TNP	D. Van Cleve

Liver

Bases-GC/NPD &/or MS	Basic Drugs	ND	R. Cabrera
Sympath. Amines-GC/MS	Amphetamine	ND	D. Van Cleve
Sympath. Amines-GC/MS	Ephedrine	ND	D. Van Cleve
Sympath. Amines-GC/MS	Methamphetamine	ND	D. Van Cleve
Sympath. Amines-GC/MS	Methylenedioxymphetamine (MDA)	ND	D. Van Cleve
Sympath. Amines-GC/MS	Methylenedioxymethamphetamine (MDMA)	ND	D. Van Cleve
Sympath. Amines-GC/MS	Pseudoephedrine	ND	D. Van Cleve

A Hunt / Lucas

CASE REPORT

DEPARTMENT OF CORONER

CITY OF LOS ANGELES

APPARENT MODE

ACCIDENT

CASE NO

2020-00803

SPECIAL CIRCUMSTANCES

CRYPT

25

1

LAST, FIRST MIDDLE

DOE, JOHN

AKA

#

ADDRESS

CITY

STATE

ZIP

SEX RACE APPEARS  
MALE ARMENIAN

DOB

AGE

HGT

in.

WGT

140 lbs.

EYES

UNKNOW

HAIR

GRAY

TEETH

FACIAL HAIR

ID VIEW

No

CONDITION

POOR CONDITION

MARK TYPE MARK LOCATION MARK DESCRIPTION

NOK

ADDRESS

CITY

STATE

ZIP

PLEASE SEE CASE NOTES

RELATIONSHIP

PHONE

NOTIFIED BY

DATE

TIME

SSN

DL ID

STATE

PENDING BY

ID METHOD

FINGERPRINTS FROM FBI

LA #

MAIN #

CI #

FBI #

MILITARY #

POB

IDENTIFIED BY NAME (PRINT)

RELATIONSHIP

PHONE

DATE

TIME

FBI FINGERPRINTS

1/27/2020

PLACE OF DEATH / PLACE FOUND

ADDRESS OR LOCATION

CITY

ZIP

MOUNTAIN SIDE

4232 LA VIRGENES RD

CALABASAS

91303

PLACE OF INJURY  
MOUNTAIN SIDE

AT WORK

No

DATE

1/26/2020

TIME

LOCATION OR ADDRESS

4232 LA VIRGENES RD., CALABASAS, CA

ZIP

91303

DOB

1/26/2020

TIME

10:10

FOUND OR PRONOUNCED BY

LACFD SMITH

OTHER AGENCY INV. OFFICER

PHONE

REPORT NO.

NOTIFIED BY

NO

TRANSPORTED BY

OTHER

TO

LOS ANGELES FSC

DATE

1/27/2020 17:55

FINGERPRINTS?

Yes

CLOTHING

Yes

PARPT

No

MORTUARY

MED. EV.

No

INVEST. PHOTO #

0

SEAL TYPE

HOSP RPT

No

PHYS. EV.

No

EVIDENCE LOG

No

PROPERTY?

No

HOSP CHART

No

SUICIDE NOTE

No

GSR NO

RCPT. NO.

PF NO.

SYNOPSIS

THE DECEDENT WAS ONE OF NINE INDIVIDUALS INVOLVED IN A HELICOPTER CRASH ON 01/26/2019. ON 01/26/2019 A SIKORSKY S-76B THAT THE DECEDENT WAS RIDING IN CRASHED INTO MOUNTAINOUS TERRAIN IN THE CITY OF CALABASAS. WEATHER CONDITIONS AT THE TIME OF THE COLLISION WERE REPORTED TO BE FOGGY. THE HELICOPTER APPEARS TO HAVE CRASHED INTO A MOUNTAIN BEFORE MAKING A SMALL SKIP AND COMING TO REST NEAR A HIKING TRAIL. THE TAIL OF THE HELICOPTER WAS LOCATED SOUTH OF THE MAIN BODY OF THE HELICOPTER. VARIOUS AIRCRAFT PARTS WERE STREWN FOR APPROXIMATELY 100 YARDS NORTH OF THE APPARENT MAIN POINT OF IMPACT. THE DECEDENT WAS OBSERVED LYING ON THE VEGETATION COVERED GROUND SOUTHEAST OF THE MAIN WRECKAGE. A SEATBELT WAS NOTED TO BE SECURED AROUND HIS WAIST. HE IS REPORTED TO BE THE PILOT OF THE HELICOPTER.

KRISTINA MCGUIRE

547544

*K. McGuire*

INVESTIGATOR

DATE

1/28/2020

REVIEWED BY

*[Signature]*

TIME

00:03

DATE

1/28/20

TIME

00:06

Coroner Case Number: 2020-00803 Decedent: ZOBAYAN, ARA

SPECIMEN    SERVICE                      DRUG    RESULT              ANALYST

NOTE:AKA John Doe. \*Analysis performed in singlet due to limited specimen volume; result may not be Title 17 compliant. \*\*Test not performed due to insufficient specimen volume.

<b>Legend:</b>		ND	Not Detected	SNS	Specimen Not Suitable
g	Grams	ng/g	Nanograms per Gram	TNP	Test Not Performed
g%	Gram Percent	ng/mL	Nanograms per Milliliter	ug	Micrograms
Inc.	Inconclusive	PP	Presumptive Positive	ug/g	Micrograms per Gram
mg	Milligrams	QNS	Quantity Not Sufficient	ug/mL	Micrograms per Milliliter

The alcohol analysis was performed in accordance to California Code of Regulations "Title 17" compliance by a qualified analyst in the Forensic Toxicology Laboratory, Forensic Laboratories Division, County of Los Angeles Department of Medical Examiner - Coroner.

Enzyme-linked immunosorbant assay (ELISA) provides only a preliminary analytical result that is contingent upon a confirmatory test. A "presumptive positive" (PP) signifies a detection of a drug class and must be confirmed by additional testing for true identification and/or quantitation of specific drug(s) present in the specimen.

Per the Department's Evidence Retention Policy, the blood specimen(s) will be retained for one year (minimum) and all other specimens six months (minimum) from Autopsy.

Final Review By:



Sarah Buxton de Quintana  
Supervising Criminalist I

Date:

2/21/20

*The above results relate only to the items sampled and tested and have been technically and administratively reviewed and are the opinions and conclusions of the analysts noted. The final review has been certified by the noted Toxicologist to ensure that all standard operating procedures were followed as set by the Forensic Toxicology Laboratory, Forensic Sciences Laboratory Division, County of Los Angeles Department of Medical Examiner-Coroner.*

# CASE REPORT

DEPARTMENT OF CORONER

1

APPARENT MODE  
**ACCIDENT**

CASE NO  
**2020-00803**

SPECIAL CIRCUMSTANCES  
**At Work, Media Interest, Multiple Deaths**

CRYPT  
**25**

LAST FIRST MIDDLE  
**BOBAYAN, ARA**

AKA #

ADDRESS CITY STATE ZIP  
**6972 PACIFIC COAST HIGHWAY #104 HUNTINGTON BEA CA 92649**

SEX	RACE APPEARS	DOB	AGE	HGT	WGT	EYES	HAIR	TEETH	FACIAL HAIR	ID VIEW	CONDITION
MALE	ARMENIAN	1/2/1970	50	in.	140 lbs.	UNKNOWN	GRAY			No	POOR CONDITION

MARK TYPE MARK LOCATION MARK DESCRIPTION

ADDRESS CITY STATE ZIP

RELATIONSHIP PHONE NOTIFIED BY DATE TIME  
INV. K. MCGUIRE 1/27/2020

SSN DL ID STATE PENDING BY

ID METHOD  
**FINGERPRINTS FROM FBI**

LA# MARK# CII# FBI# MILITARY# POB

IDENTIFIED BY NAME (PRINT) RELATIONSHIP PHONE DATE TIME  
**FBI FINGERPRINTS 1/27/2020**

PLACE OF DEATH / PLACE FOUND ADDRESS OR LOCATION CITY ZIP  
**MOUNTAIN SIDE 4232 LAS VIRGENES RD CALABASAS 91303**

PLACE OF INJURY AT WORK DATE TIME LOCATION OR ADDRESS ZIP  
**MOUNTAINSIDE Yes 1/26/2020 4232 LAS VIRGENES RD., CALABASAS, CA 91303**

DOD TIME FOUND OR PRONOUNCED BY  
**1/26/2020 10:10 LACFD SMITH**

OTHER AGENCY INV. OFFICER PHONE REPORT NO. NOTIFIED BY NO

TRANSPORTED BY TO DATE TIME  
**OTHER LOS ANGELES FSC 1/27/2020 17:55**

FINGERPRINTS?	Yes	CLOTHING	Yes	PART	No	MORTUARY	FOREST LAWN HWD. HILLS
MED. EV.	No	INVEST. PHOTO #	0	SEAL TYPE		HOSP RPT	No
PHYS. EV.	No	EVIDENCE LOG	No	PROPERTY?	No	HOSP CHART	No
SUICIDE NOTE	No	GSR NO		RCPT. NO.		PF NO.	

**SYNOPSIS**  
THE DECEDENT WAS ONE OF NINE INDIVIDUALS INVOLVED IN A HELICOPTER CRASH ON 01/26/2019. ON 01/26/2019 A SIKORSKY S-76B THAT THE DECEDENT WAS RIDING IN CRASHED INTO MOUNTAINOUS TERRAIN IN THE CITY OF CALABASAS. WEATHER CONDITIONS AT THE TIME OF THE COLLISION WERE REPORTED TO BE FOGGY. THE HELICOPTER APPEARS TO HAVE CRASHED INTO A MOUNTAIN BEFORE MAKING A SMALL SKIP AND COMING TO REST NEAR A HIKING TRAIL. THE TAIL OF THE HELICOPTER WAS LOCATED SOUTH OF THE MAIN BODY OF THE HELICOPTER. VARIOUS AIRCRAFT PARTS WERE STREWN FOR APPROXIMATELY 100 YARDS NORTH OF THE APPARENT MAIN POINT OF IMPACT. THE DECEDENT WAS OBSERVED LYING ON THE VEGETATION COVERED GROUND SOUTHEAST OF THE MAIN WRECKAGE. A SEATBELT WAS NOTED TO BE SECURED AROUND HIS WAIST. HE IS REPORTED TO BE THE PILOT OF THE HELICOPTER.


KRISTINA MCGUIRE 547544 <i>K. McGuire</i> INVESTIGATOR	DATE 1/28/2020 TIME 00:03	REVIEWED BY LARRY DIETZ <i>Larry Dietz</i>	DATE 1/28/2020 TIME 00:19
---	------------------------------------	---	------------------------------------

FORM #3 NARRATIVE TO FOLLOW?

MED. EV.	No	INVEST. PHOTO #	0	SEAL TYPE		HOSP RPT	No
PHYS. EV.	No	EVIDENCE LOG	No	PROPERTY?	No	HOSP CHART	No
SUICIDE NOTE	No	GSR NO		RCPT. NO.		PP NO.	

**SYNOPSIS**

THE DECEDENT WAS ONE OF NINE INDIVIDUALS INVOLVED IN A HELICOPTER CRASH ON 01/26/2019. ON 01/26/2019 A SIKORSKY S-76B THAT THE DECEDENT WAS RIDING IN CRASHED INTO MOUNTAINOUS TERRAIN IN THE CITY OF CALABASAS. WEATHER CONDITIONS AT THE TIME OF THE COLLISION WERE REPORTED TO BE FOGGY. THE HELICOPTER APPEARS TO HAVE CRASHED INTO A MOUNTAIN BEFORE MAKING A SMALL SKIP AND COMING TO REST NEAR A HIKING TRAIL. THE TAIL OF THE HELICOPTER WAS LOCATED SOUTH OF THE MAIN BODY OF THE HELICOPTER. VARIOUS AIRCRAFT PARTS WERE STREWN FOR APPROXIMATELY 100 YARDS NORTH OF THE APPARENT MAIN POINT OF IMPACT. THE DECEDENT WAS OBSERVED LYING ON THE VEGETATION COVERED GROUND SOUTHEAST OF THE MAIN WRECKAGE. A SEATBELT WAS NOTED TO BE SECURED AROUND HIS WAIST. HE IS REPORTED TO BE THE PILOT OF THE HELICOPTER.

KRISTINA MOGUIRE  
 547544  


INVESTIGATOR \_\_\_\_\_ DATE 1/28/2020 REVIEWED BY LARRY DIETZ  
 TIME 00:03 TIME 00:19

FORM #3 NARRATIVE TO FOLLOW?



County of Los Angeles, Department of Coroner  
Investigator's Narrative



Case Number: 2020-00803

Decedent: ZOBAYAN, ARA

**Information Sources:**

1. Aircraft Accident Investigation Report, National Transportation Safety Board, Washington D.C. 20594.
2. On scene investigation.

**Investigation:**

Initial reports indicate that on 01/26/2020 at approximately 0945 hours multiple witnesses called 911 reporting that a helicopter had crashed into the foothills of the Santa Monica mountains above Las Virgenes Road in the City of Calabasas. Deputies from the Los Angeles County Sheriff's Department and personnel from the Los Angeles County Fire Department responded to the scene. Upon arrival to the scene nine decedents were located and pronounced dead at 1010 hours by Los Angeles County Fire Department personnel.

On 01/26/2020 at 1338 hours Officer Rodriguez from the Los Angeles County Sheriff's Department-Homicide Bureau called to report this multi-decedent helicopter crash fatality to Investigator Jeffrey Guilmette at the Los Angeles County Department of the Medical Examiner-Coroner. I was assigned this Special Operations Response Team (SORT) field case at 1400 hours by Acting Supervisor Anthony Lopez. I arrived on scene at approximately 1620 hours and cleared the scene at approximately 1930 hours. On 01/26/2020 the following SORT team members responded to the scene for a coordinated search and decedent removal:

M. Lee #605743, L. Cervantes #639654, P. Ngayan #531611, B. Kim #602036, E. Napoles #465129, M. Gutierrez #479704, R. Estrada #486093, R. Gonzalez #503064, J. Fallot #644073.

On 01/27/2020 at approximately 0630 hours I returned to the scene and cleared the scene at approximately 1600 hours. On 01/27/2020 the following SORT Team Members returned to the scene for a continued coordinated search and decedent removal:

M. Lee #605743, L. Cervantes #639654, P. Ngayan #531611, B. Kim #602036, E. Napoles #465129, M. Gutierrez #479704, R. Estrada #486093, R. Gonzalez #503064, J. Fallot #644073. F. Fernandez #486349, M. Molina #421452.

Forensic Attendant P. Ngayan transported all decedents to the Forensic Science Center.

Also present at the scene were Chief B. Elias, Captain E. Tauscher and Dr. J. Lucas.

**Location:**

Place of Injury/Death: Mountainside, 4232 Las Virgenes Road, Calabasas, CA 91303.

**Informant/Witness Statements:**

A review of a report issued by the National Transportation Safety Board revealed the following information:

On 01/26/2020 at 0945 hours a Sikorsky S-76B helicopter, N72EX, collided with hilly terrain near the city of Calabasas. The helicopter held 8 passengers and a pilot who were all killed on impact. The Sikorsky was in an 8-passenger seat configuration with two pilot stations up front and eight passengers in the rear, separated by a bulkhead with sliding acrylic windows. Passenger seating was 2 four-occupant divans, one facing forward and the other rearward. A main impact crater measuring 24 feet by 15 feet in diameter was observed with the main wreckage noted to be about 127 feet along a 347° true bearing from the impact crater. The helicopter was destroyed by impact forces and fire with the entire fuselage/cabin and both engines subjected to a post-crash fire.



County of Los Angeles, Department of Coroner  
Investigator's Narrative



Case Number: 2020-00803

Decedent: ZOBAYAN, ARA

**Scene Description:**

The scene is mountainous, vegetation covered terrain located east of 4232 Las Virgenes Road in the City of Calabasas. Due to the size of the scene a stake was placed at a central point located just north of what appears to be the main fuselage. The GPS coordinates of the stake were 34°8'14" N and 118°41'33" W. What appeared to be an initial point of impact designated by a disturbance to the soil and vegetation and various helicopter parts, personal property and human remains were located approximately 120 feet south of the designated central stake. The helicopter wreckage, personal property and human remains were spread in a cone shape across the area starting at the initial point of impact and spreading toward the north stopping at the north side of a ravine. A designated hiking path was located surrounding the scene.

**Evidence:**

No evidence was collected for this case.

**Body Examination:**

The decedent is an adult Caucasian male I observed in a seated position on the vegetation covered ground southeast of the main wreckage. His body was bent at the waist with his bilateral legs outstretched from his body and his upper body leaning toward his left. He was wearing a white shirt, gray sweater, black jacket, black pants, black belt, black underwear, black socks and black boots. He has gray hair and an unknown eye color. Upon external examination I noted significant trauma to his head, bilateral arms and lower body.

**Identification:**

On 01/27/2020 at 1854 hours the decedent was positively identified as Ara Zobayan (DOB: 01/02/1970) via Federal Bureau of Investigation fingerprints.

**Next of Kin Notification:**

██████████ decedent was notified of the decedent's death by other family members. I provided telephonic notification of the decedent's death to ██████████ the decedent.

**Tissue Donation:**

Not addressed.

**Autopsy Notification:**

No exam request was noted.

KRISTINA MCGUIRE  
#547544

SUPERVISOR

02/13/2020

Date of Report