

See discussions, stats, and author profiles for this publication at: <https://www.researchgate.net/publication/357569976>

Keratoconus: An updated review

Article in *Contact lens & anterior eye: the journal of the British Contact Lens Association* · January 2022

DOI: 10.1016/j.clae.2021.101559

CITATIONS

48

READS

814

6 authors, including:



Jacinto Santodomingo-Rubido

Menicon Co. Ltd.

70 PUBLICATIONS 2,602 CITATIONS

SEE PROFILE



Gonzalo Carracedo

Complutense University of Madrid

91 PUBLICATIONS 1,137 CITATIONS

SEE PROFILE



Asaki Suzuki

Menicon Co., Ltd. Nagoya, Japan

11 PUBLICATIONS 297 CITATIONS

SEE PROFILE



Cesar Villa Collar

European University of Madrid

193 PUBLICATIONS 3,016 CITATIONS

SEE PROFILE

Some of the authors of this publication are also working on these related projects:



Contact lens prescribing trends [View project](#)




International Contact Lens Prescribing [View project](#)



Contents lists available at ScienceDirect

Contact Lens and Anterior Eye

journal homepage: www.elsevier.com/locate/clae

Keratoconus: An updated review

Jacinto Santodomingo-Rubido^{a,*}, Gonzalo Carracedo^b, Asaki Suzaki^c, Cesar Villa-Collar^d,
Stephen J. Vincent^e, James S. Wolffsohn^f

^a Global R&D, Menicon Co. Ltd, Nagoya, Japan

^b Department of Optometry and Vision, Faculty of Optics and Optometry, Universidad Complutense de Madrid, Madrid, Spain

^c Clinical Research and Development Center, Menicon Co., Ltd., Nagoya, Japan

^d Department of Pharmacy, Biotechnology, Nutrition, Optics and Optometry, Faculty of Biomedical and Health Sciences, Universidad Europea de Madrid, Madrid, Spain

^e Contact Lens and Visual Optics Laboratory, School of Optometry and Vision Science, Centre for Vision and Eye Research, Queensland University of Technology, Brisbane, Australia

^f School of optometry, Health and Life Sciences, Aston University, Birmingham B4 7ET, United Kingdom

ARTICLE INFO

Keywords:

Epidemiology
Detection
Classification
Histopathology
Aetiology
Management

ABSTRACT

Keratoconus is a bilateral and asymmetric disease which results in progressive thinning and steeping of the cornea leading to irregular astigmatism and decreased visual acuity. Traditionally, the condition has been described as a noninflammatory disease; however, more recently it has been associated with ocular inflammation. Keratoconus normally develops in the second and third decades of life and progresses until the fourth decade. The condition affects all ethnicities and both sexes. The prevalence and incidence rates of keratoconus have been estimated to be between 0.2 and 4,790 per 100,000 persons and 1.5 and 25 cases per 100,000 persons/year, respectively, with highest rates typically occurring in 20- to 30-year-olds and Middle Eastern and Asian ethnicities. Progressive stromal thinning, rupture of the anterior limiting membrane, and subsequent ectasia of the central/paracentral cornea are the most commonly observed histopathological findings. A family history of keratoconus, eye rubbing, eczema, asthma, and allergy are risk factors for developing keratoconus. Detecting keratoconus in its earliest stages remains a challenge. Corneal topography is the primary diagnostic tool for keratoconus detection. In incipient cases, however, the use of a single parameter to diagnose keratoconus is insufficient, and in addition to corneal topography, corneal pachymetry and higher order aberration data are now commonly used. Keratoconus severity and progression may be classified based on morphological features and disease evolution, ocular signs, and index-based systems. Keratoconus treatment varies depending on disease severity and progression. Mild cases are typically treated with spectacles, moderate cases with contact lenses, while severe cases that cannot be managed with scleral contact lenses may require corneal surgery. Mild to moderate cases of progressive keratoconus may also be treated surgically, most commonly with corneal cross-linking. This article provides an updated review on the definition, epidemiology, histopathology, aetiology and pathogenesis, clinical features, detection, classification, and management and treatment strategies for keratoconus.

1. Introduction

In 2010, a comprehensive review of keratoconus was published in *Contact Lens & Anterior Eye*, which became the most cited article of the journal to date [1]. This article reviewed the definition, epidemiology, clinical features, classification, histopathology, aetiology and pathogenesis, and management and treatment strategies for keratoconus. Over the last decade, numerous epidemiological studies have been conducted allowing for better estimates of the incidence and prevalence

of keratoconus. Many other studies have also contributed to a better understanding of keratoconus, particularly due to the adoption of new technologies for imaging the human cornea. Improvements in corneal topography and the advent of corneal tomography has increased the ability of eye care practitioners to diagnose corneal ectasia at a much earlier stage than was previously possible. These imaging techniques, along with the increased use of wavefront aberrometry, have allowed better characterisation of the optical, anatomical, biomechanical and histopathological changes associated with keratoconus [2]. The latter,

* Corresponding author at: Global R&D, Menicon Co. Ltd, Nagoya, Japan.

E-mail address: j.santodomingo@menicon.com (J. Santodomingo-Rubido).

<https://doi.org/10.1016/j.clae.2021.101559>

Received 19 August 2021; Received in revised form 23 November 2021; Accepted 12 December 2021

1367-0484/© 2021 The Authors. Published by Elsevier Ltd on behalf of British Contact Lens Association. This is an open access article under the CC BY license

(<http://creativecommons.org/licenses/by/4.0/>).

together with recent developments of contact lens and surgical options for keratoconus, have ultimately lead to improved clinical management [3,4]. The present article provides an updated review of keratoconus and expands on areas of recently acquired knowledge. In preparing this review, each author was given the lead to prepare one or more of the different sections or subsections covered in the review, although some sections/subsections had contributions from other authors. Adopting a search strategy using the keywords “keratoconus” and “definition” or “epidemiology” or “histopathology” or “aetiology” or “pathogenesis” or “features” or “clinical features” or “detection” or “classification” or “management” or “treatment”, articles were retrieved from two search databases (i.e., PubMed and Embase). Other searches were also made using different combinations of key terms at the authors’ discretion. Articles available in the database from their inception to between January and July 2021 were included, with the cut-off date for the search for articles being freely chosen by each individual author, although other articles were added to this review at a later date as part of the review process. Pertinent articles for each section were identified; abstracts reviewed; and relevant papers read in full, along with additional relevant papers identified in the reference lists. When several research papers reporting on similar findings appeared during the literature search, the most updated article(s) was typically used for review.

2. Definition

The word keratoconus derives from the Greek words ‘kérās’, meaning cornea, and ‘cōnus’, meaning cone, which together means ‘cone-shaped’ cornea. Although the presentation, clinical features, and refractive consequences of keratoconus were described with reasonable accuracy by a few European oculists in the early 18th and 19th centuries, it was not until 1854 that John Nottingham provided a comprehensive understanding of what is currently understood as keratoconus, which allowed the condition to be distinguished from other corneal ectasias [5].

Today, keratoconus is considered a bilateral and asymmetric ocular disease which results in progressive thinning and steepening of the cornea leading to irregular astigmatism and decreased visual acuity [6–8]. Corneal thinning occurs in the central or paracentral cornea, most commonly infero-temporally [9]. Traditionally, keratoconus has been described as a noninflammatory disease [10,11]; however, several studies have reported associations with significant alterations in inflammatory mediators [12–16], indicating that keratoconic eyes often experience some form of ocular inflammation [12,17,18]. Although a bilateral condition, one eye is typically more severely affected than the other [19–23]. The condition affects all ethnicities and both sexes. It is commonly an isolated ocular condition, but sometimes coexists with other ocular and systemic diseases [10].

3. Epidemiology

Determining the prevalence and incidence of a particular disease is critical, because it can aid in identifying potential underlying causative factors, assessing methods to prevent, monitor, and treat the condition [24], and formulate and evaluate healthcare policies [25]. The prevalence of a condition is defined as ‘the part (percentage or proportion) of a defined population affected by a particular medical disorder at a given point in time, or over a specified period of time’ while the incidence rate represents ‘the frequency of new occurrences of a medical disorder in the studied population at risk of the medical disorder arising in a given period of time’ [25]. The prevalence of a condition is assessed in a cross-sectional sample, and the incidence is assessed employing longitudinal study designs [26].

Early studies in which the diagnosis of keratoconus was based upon the scissor movement observed during retinoscopy, irregular keratometry mires, and the subjective assessment of clinical signs were more

likely to identify advanced keratoconus. However, the widespread use of corneal topography, and more recently corneal tomography, together with built-in software to aid in keratoconus detection has facilitated the ability to diagnose patients with keratoconus even at incipient stages of the disease, ultimately leading to greater rates of keratoconus being reported in studies conducted in recent years (Table 1).

Epidemiological studies indicate substantial global variation as the prevalence and incidence rates of keratoconus have been estimated to be between 0.2 and 4,790 per 100,000 persons and 1.5 and 25 per 100,000 persons/year, respectively (Table 1; Figs. 1 and 2), with the highest prevalence and incidence rates typically occurring in 20 to 30 year olds [27–29]. Differences between studies have been attributed to differences in geographic location and ethnicity, the definition of keratoconus and diagnostic criteria, study design, and the age and cohort of subjects assessed (Table 1; Figs. 1 and 2). Furthermore, fair comparisons between studies of keratoconus are difficult to make due to differences in the criteria used for defining the numerators and denominators used for calculating the incidence and prevalence rates [25].

In hospital/clinic-based studies, a high prevalence of keratoconus has been reported in the Middle East with rates up to 4,790 per 100,000 in Saudi Arabia adolescents [53] compared to 0.2 to 0.4 per 100,000 in Russia [34] (Table 1 and Fig. 1). Incidence rates of keratoconus from hospital/clinic studies have been reported to be as low as 1.5 per 100,000 persons/year in Finland [32] to over 20 per 100,000 persons/year in Asian and Middle East populations [35,37,38] (Table 1 and Fig. 2). However, hospital/clinic-based epidemiological data should be interpreted with caution since the true prevalence of keratoconus within the wider population may be underestimated. Patients with keratoconus presenting to a hospital/clinic are likely to be those who are symptomatic and with access to health care, thus early forms of the disease might not be detected. Furthermore, these studies do not take into account the number of patients treated outside of the hospital/clinic(s) where the study is conducted [29]. Therefore, population-based epidemiological studies provide a more representative estimate of the true prevalence and incidence of keratoconus in the general population. In population based studies, the prevalence of keratoconus has been reported to be as low as 4 in Denmark [54] and up to 22 per 100,000 persons in the Middle East [45] (Table 1 and Fig. 1), and the incidence of keratoconus has been reported to be as low as 3.6 in Denmark [54], up to 22.3 per 100,000 persons/year in Iran [45] (Table 1 and Fig. 2).

The prevalence and incidence of keratoconus varies with regard to ethnicity and geographical location (Table 1 and Figs. 1 and 2). Studies of predominantly Caucasian populations report prevalence rates under 1,000 per 100,000 persons, whereas studies conducted in Asian and Middle East populations report prevalence rates between 1,500 and 5,000 per 100,000 persons. Similarly, the incidence of keratoconus in Caucasians appears to be around 2 to 4 per 100,000 persons/year compared to around 20 per 100,000 persons/year in Asia and the Middle East. Two studies conducted in the United Kingdom found a significantly higher prevalence and incidence of keratoconus in Asians (primarily Indian and Pakistani) compared to Caucasians [35,37] which might indicate that such differences are related to ethnicity rather than geographic location. Similarly, a more recent study of high school students in New Zealand found a significantly higher prevalence of keratoconus in Maori islanders in comparison with a predominantly Caucasian cohort [55].

Although some studies have reported greater rates of keratoconus in males, many studies have found the opposite (or no significant difference), which most likely indicates that keratoconus affects both sexes similarly (Table 1).

4. Histopathology

All corneal layers have been reported to experience histopathological changes in keratoconus, which are much more pronounced in the central compared to the peripheral cornea; however, in early forms of the

Table 1

Prevalence and incidence rates of keratoconus reported as per 100,000 persons and 100,000 person-years, respectively in studies conducted around the world. NA, not available; ^aReported prevalence for definite keratoconus cases only; ^bAsian are mostly Indian; ^cAsian are mostly Pakistani; ^dPrevalence recalculated based on number of subjects rather than number of eyes; ^eCorrected value provided by study author (personal communication); ^fPopulation-based studies with claims health data from national or insurance registration.

Study	Year	Location	Sample Size (Catchment Population/n ^a keratoconus)	Population mean/median Age [range] (years)	Diagnostic criteria	Study Duration (years)	Study Design	Source	Incidence [95% CI]	Prevalence [95% CI]	Male/Female ratio
Hofstetter [30]	1959	Indianapolis, USA	13,395/16 eyes	NA [1-78]	Placido-disc keratometry	0.03	Prospective, cross-sectional	Population	NA	120 (0.12%) [NA] ^a	0.22
Tanabe et al. [31]	1985	Japan	8,539,000/742 subjects	NA [25-29]	NA	21	Retrospective, cross-sectional	Population	NA	9 (0.009%) [NA]	2.86
Ihalainen [32]	1986	Finland	260,000/75 patients	NA [15-69]	Retinoscopy + keratometry	20	Retrospective	Hospital/clinic	1.5	30 (0.03%) [NA]	1.68
Kennedy et al. [8]	1986	Minnesota, USA	Census data/64 subjects	25 [12-76]	Retinoscopy + keratometry	48	Retrospective	Hospital/clinic	2.0 [NA]	54.5 (0.0545%) [NA]	1.2
Santiago et al. [33]	1995	France	670/18 subjects	NA [18-22]	Topography (power and indices)	NA	Prospective, cross-sectional	Population (Army recruits)	NA	750 (0.75%) [NA]	NA
Gorskova and Sevost'ianov [34]	1998	Urals, Russia	NA	NA	NA	NA	NA	Hospital/clinic	NA	0.2-0.4 (0.0002-0.0004%) [NA]	3
Pearson et al. [35]	2000	Midlands, United Kingdom	~900,000/271 patients for incidence and 338 patients for prevalence	NA [10-44]	Diagnosis by ophthalmologist	10	Retrospective	Hospital/clinic	Asian ^b = 19.6 [7.0-31.3] White = 4.5 [1.7-7.3]	Asian ^b = 229 (0.229%) [NA] White = 57 (0.057%) [NA]	Asian ^b = 1.5 Whites = 1.85
Ota et al [36]	2002	Tokyo, Japan	2,456,406 /220 patients	NA [15-34]	NA	1	Retrospective, longitudinal	Hospital/clinic	9 [NA]	NA	2.31
Georgiou et al [37]	2004	United Kingdom	176,774/74 patients	NA [13-36]	History of progressive, irregular, myopic astigmatism, and clinical signs	6	Retrospective, longitudinal	Hospital/clinic	Asian ^c = 25 White = 3.3	NA	2.52
Assiri et al. [38]	2005	Asir, Saudi Arabia	654,163/125 patients	NA [6-28]	Visual acuity, family history, keratometry, retinoscopy, ophthalmoscopy, and clinical signs	1	Prospective	Hospital/clinic	20 [NA]	NA	0.69
Jonas et al [39]	2009	Maharashtra, India	4,677/128 subjects	Entire sample: 49.5 ± 13.4 [30 to 100]	Keratometry > 48D	NA	Prospective, cross-sectional	Population	NA	2737 (2.737%) [10.3-36.7] ^d	0.29
Ljubic [40]	2009	Skope, Macedonia	2 million/136 ^e subjects	Entire sample: NA Keratoconus cohort: 26.81 ± 1.25 [NA] ≥ 65	Keratometry ≥ 48D	8	Retrospective, longitudinal	Hospital/clinic	NA	6.8 (0.0068%) [NA]	1.13
Reeves et al. [41]	2009	USA	5% Medicare beneficiaries ≥ 65 years/1165	NA	NA	5	Longitudinal, retrospective, cross-sectional	Population	NA	17.5 (0.0175%) [NA]	No difference
Millodot et al. [42]	2011	Jerusalem, Israel	981/23 subjects	Entire sample: 24.4 ± 5.7 [18-54] Keratoconus cohort: NA	Topography (power, pattern, and indices)	1.33	Prospective, cross-sectional	Population (college students)	NA	2340 (2.340%) [1400-3300]	2.28
Waked et al. [43]	2012	Beirut, Lebanon	92/3	Entire sample: 23.6 ± 1 [22-26]	Questionnaire + Topography	0.33	Prospective, cross-sectional	Hospital/clinic (medical students)	NA	3261 (3.261%) [NA]	1.43
Xu et al. [44]	2012	Beijing, China	3468/27	NA	NA	NA	NA	NA	NA	NA	0.17

(continued on next page)

Table 1 (continued)

Study	Year	Location	Sample Size (Catchment Population/n° keratoconus)	Population mean/median Age [range] (years)	Diagnostic criteria	Study Duration (years)	Study Design	Source	Incidence [95% CI]	Prevalence [95% CI]	Male/Female ratio
				Entire sample: 64.6 ± 9.8 [50-92] Keratoconus cohort: 64.2 ± 11.3	Optical low-coherence reflectometry ≥ 48D		Prospective, cross-sectional	Population (subjects ≥ 50 years)		900 (0.9%) [600–1200]	
Ziaei et al [45]	2012	Yazd, Iran	990,818/536 subjects	Entire sample: NA Keratoconus group: 25.7 ± 9	Topography (pattern and indices) + clinical examination	1	Prospective	Population	22.3 [19.5–25.4]	NA	1.11
Hashemi et al. [46]	2013	Shahroud, Iran	4592/35	Entire sample: 50.83 ± 0.12 [40-64] Keratoconus cohort: 47.6 ± 4.7 [NA]	Topography (Holladay criteria)	NA	Prospective, cross-sectional	Population	NA	760 (0.76%) [510–1010]	0.58
Hashemi et al. [47]	2013	Teheran, Iran	426/14	Entire sample: 40.8 ± 17.1 [14-80] Keratoconus cohort: 53.6 ± 14.9 [22-74]	Topography + thinnest corneal point	NA	Prospective, cross-sectional	Population	NA	3300 (3.3%) [1000–5500]	0.75
Hashemi et al. [48]	2014	Mashhad, Iran	1027/26	Entire sample: 26.1 ± 2.3 [20-34] Keratoconus cohort: NA	Topography + thinnest corneal point	NA	Prospective, cross-sectional	Population (university students)	NA	2500 (2.5%) [1600–3500]	0.86
Shneor et al. [49]	2014	Haifa, Israel	314/10	Entire sample: 25.1 ± 8.8 [18-60] Keratoconus cohort: 25.1 ± 8.8 [19-28]	Topography (power and indices) + clinical examination	0.42	Prospective, cross-sectional	Population (university students)	NA	3180 (3.18%) [1200–5100]	0.25
Valdez-García et al. [50]	2014	Monterrey, Mexico	500/9 subjects	Entire sample: NA [10-20] Keratoconus cohort: 16.1 [NA]	NA	NA	Retrospective, cross-sectional	Hospital/clinic	NA	1800 (1.8%) [0–30]	0.33
Shehadeh et al. [51]	2015	Nablus, Palestine	620/9	Entire sample: 20.1 ± 1.6 [17-27] Keratoconus cohort: NA	Topography indices	NA	Prospective, cross-sectional	Population (university students)	NA	1500 (1.5%) [NA]	Higher in females
Godefrooij et al ^f [52]	2017	The Netherlands	1,635,517/218 for incidence 4,357,044/NA for prevalence	Entire sample: NA [10-40] Keratoconus cohort: NA	Diagnosis by ophthalmologist	1	Retrospective, longitudinal	Population	13.3 [11.6–15.2]	265 (0.265%) [256-266]	1.54
Hwang et al ^f [28]	2018	South Korea	47,990,761/ 17,931 for prevalence 47,986,173/	Entire sample: NA Keratoconus cohort (prevalence):	Diagnosis by ophthalmologist	6 for prevalence 5 for incidence	Retrospective, longitudinal	Population	5.66 [5.47–5.66]	37.36 (0.03736%) [36.82–37.91]	1.00

(continued on next page)

Table 1 (continued)

Study	Year	Location	Sample Size (Catchment Population/n° keratoconus)	Population mean/median Age [range] (years)	Diagnostic criteria	Study Duration (years)	Study Design	Source	Incidence [95% CI]	Prevalence [95% CI]	Male/ Female ratio
			13,343 for incidence	31.2 ± 14.2[0- >85] Keratoconus cohort (incidence): 31.9 ± 15.1 [0- >85]							
Torres Netto et al. [53]	2018	Riyadh, Saudi Arabia	522/25 patients	Entire sample: 16.8 ± 4.2 [6- 21] Keratoconus cohort: NA	Topography (power and indices) + subjective screening criteria	NA	Prospective, cross-sectional	Hospital/clinic (paediatric patients)	NA	4790 (4.79%) [2920–6620]	NA
Bak-Nielsen et al. ^f [54]	2019	Denmark	28,020,821/1008 subjects for incidence 5,707,251/2846 subjects for prevalence	NA	NA	5 for incidence 38 for prevalence	Retrospective, longitudinal	Population	3.6 [NA]	44 (0.044%) [NA]	NA
Papali'i-Curtin et al. [55]	2019	Wellington, New Zealand	1,916/10 subjects	Entire sample: 14.6 [NA] Keratoconus cohort: 14.9 [12.7– 16.1]	Topography (power, pattern and indices)	NA	Prospective, cross-sectional	Population (high school students)	NA	Entire cohort: 520 (0.52%) [NA] Maori islanders: 2250 (2.25%) [NA]	2.33
Armstrong et al. 2020 [56]	2020	Abu Dhabi, United Arab Emirates	339/9 subjects	Entire sample: NA [10-19] Keratoconus cohort: NA	Topography indices + clinical examination	0.25	Prospective, cross-sectional	Population (secondary school students)	NA	1500 (1.5%) [700–2900]	NA
Özalp et al. [57]	2021	Eskişehir, Turkey	585/14 subjects	Entire sample: 21.6 ± 2.6 [≥18 to ≤ 30] Keratoconus cohort: NA	Topography (power and indices) + pachymetry	NA	Prospective, cross-sectional	Population (university students and faculty members)	NA	2393 (2.393%) [1426–4015]	Higher in males

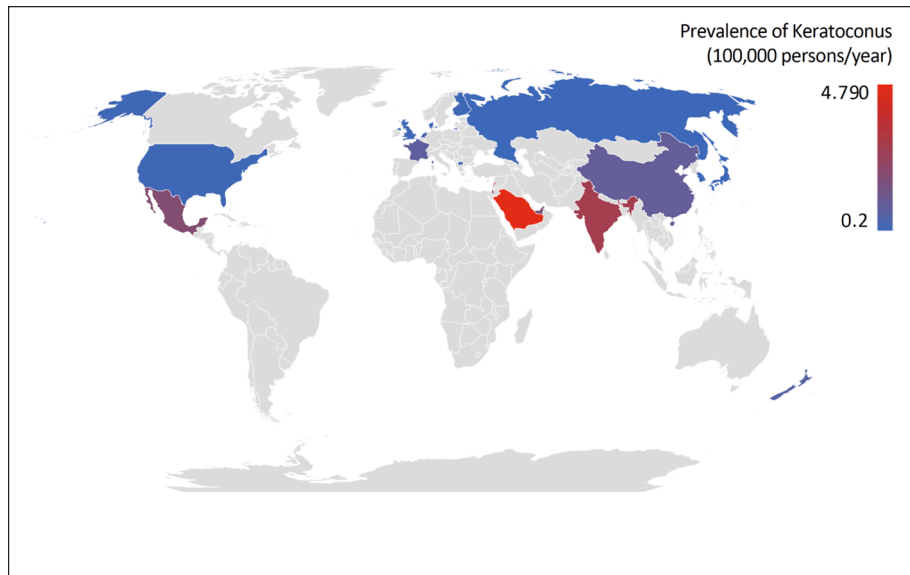


Fig. 1. Reported prevalence rates (per 100,000 persons) of keratoconus around the world. In countries where several epidemiological studies have been conducted, the results of the study with the largest sample size and those representing the most predominant ethnic group are reported.

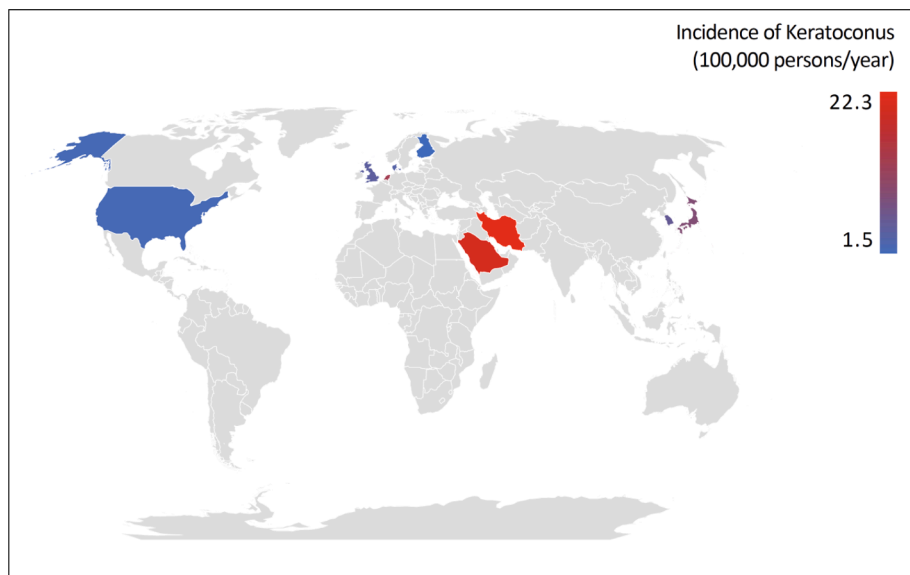


Fig. 2. Reported incidence rates (per 100,000 persons/year) of keratoconus around the world. In countries where several epidemiological studies have been conducted, the results of the study with the largest sample size and those representing the most predominant ethnic group are reported.

disease only the anterior cornea appears to be compromised [4,17,58,59]. There is some controversy as to whether the endothelium is affected in keratoconus, since many patients with keratoconus wear different types of contact lenses, including rigid corneal, corneoscleral and scleral lenses, soft and hybrid (i.e., rigid corneal lens with a peripheral soft skirt) lenses, and piggyback systems (i.e., rigid corneal lens fitted over a soft contact lens) which can alter endothelial morphology, and the endothelium can be difficult to image as the disease progresses [4,10,60]. Histopathological changes are primarily found in the corneal epithelium, anterior limiting lamina (Bowman's layer) and stroma, while the posterior limiting lamina (Descemet's membrane) appears to be much less frequently affected.

Although corneal epithelial thinning around the apical cone region is believed to be the most common histopathological change associated with keratoconus [61–63], some studies have reported either no significant change [64] or an increase in epithelial thickness [59,65].

Furthermore, one study reported that epithelial thinning was negatively correlated with disease severity [66], whereas another study found epithelial thickening was associated with breaks in the anterior limiting lamina [62]. In keratoconus, it has been proposed that epithelial thinning might occur due to apoptosis because of chronic epithelial injury subsequent to environmental risk factors, which in turn release apoptotic cytokines (see Section 5). Of interest is that the thinnest corneal location in eyes with keratoconus does not overlap with the location of the maximum axial and tangential curvatures or the maximum front and back elevation locations, although all these points are typically located in the inferior-temporal cornea. This indicates that in keratoconus the point of maximal corneal curvature is displaced relative to the thinnest corneal location [9].

The epithelium loses its cellular uniformity and is compromised by the loss or damage to the anterior limiting lamina [58], with epithelial changes being more pronounced with increasing severity of the disease

[67]. The epithelium may display basal cell degeneration, exhibiting enlargement and irregular arrangement [66,68,69], and a decrease in basal cell density compared to normal corneas [70], which correlates with disease severity [71]. Using confocal microscopy, it has been reported that in severe cases, the epithelium displays superficial cells, which are elongated and spindle shaped, larger and irregularly spaced wing cell nuclei, and flattened basal cells [67]. Breaks in the corneal epithelium, accompanied by a downgrowth of basal cells into the anterior limiting lamina, and an accumulation of ferritin particles within and between epithelial cells (most prominently in the basal layer), have also been reported in keratoconus [10,67,72]. Superficial iron deposits and scarring are other less frequently observed changes in the corneal epithelium typically affecting one in five eyes with keratoconus [62,63].

Increased visibility of corneal nerves at the sub-basal corneal nerve plexus, located between the basal epithelium and anterior limiting lamina, as a result of corneal thinning is sometimes seen in keratoconus patients with different grades of severity [6,60]. Keratoconic eyes have decreased corneal innervation, sensation, and basal and sub-basal epithelial density in comparison to normal eyes [73–75], with central sub-basal nerve density correlating with disease severity [71]. Localised nerve thickening within the epithelium has also been reported [76]. A study conducted in a small number of eyes using *in-vivo* confocal microscopy reported that keratoconic corneas exhibit abnormal sub-basal nerve architecture compared with normal corneas [73]. Furthermore, at the apex of the cone, a tortuous network of nerve fibre bundles was noted, many of which formed closed loops; and at the topographic base of the cone, nerve fibre bundles followed the contour of the cone base, with many of the bundles running concentrically in this region [73].

Breaks in the anterior limiting lamina are one of the most common histopathological signs seen in keratoconus typically affecting over seven in ten keratoconic eyes [61,62]. The breaks normally show Z-shaped interruptions due to collagen bundle separation, which are filled with proliferative collagenous tissue derived from the anterior stroma and positive nodules of Schiff's periodic acid [60,72]. Despite being acellular, cellular components have been observed in the anterior limiting lamina [62,77], including epithelial cells and stromal keratocytes [67], and anterior keratocyte nuclei have been reported to wrap around corneal nerves as they pass through this layer [76]. Hyper-reflective keratocyte nuclei observed in keratoconus are thought to indicate the presence of fibroblastic cells [67].

The well-organised architecture of the corneal stroma, which is responsible for the transparency of the cornea, is compromised in keratoconus [4]. The keratoconic cornea has been reported to show a reduction in the number of lamellae, particularly in regions associated with cone development without breaks in the anterior limiting lamina or scarring [78]. The width and angle relative to the anterior limiting lamina of collagen lamellae have been reported to be significantly larger and smaller, respectively, relative to those in the normal cornea [79]. Furthermore, it has been proposed that collagen lamellae are expanded in association with protrusion of the cone [79]. A gross rearrangement of vertical and horizontal collagen lamellae occurs in keratoconus [80]. A decrease in the interfibrillar distance of collagen sheets and the increase of proteoglycans have also been reported [81]. Ectasia and thinning in keratoconus are associated with lamellar splitting into multiple bundles of collagen fibrils and loss of anterior lamellae. These structural changes, possibly in addition to lateral shifting of lamellae due to the pressure gradient over the cornea, provide a potential explanation to the central loss of mass ultimately leading to reduced stromal thickness [82]. Alternating dark and light bands, most commonly found in the posterior stroma, have been seen in keratoconus patients using confocal microscopy [83]. These bands, which are believed to represent collagen lamellae under stress, correspond with the appearance of Vogt's striae on slit-lamp biomicroscopy examination.

Breaks and deformities in the posterior limiting lamina have been reported to occur in approximately one in five keratoconus eyes – typically affecting more severe cases [62,63]. Breakage in the posterior

limiting lamina, allowing aqueous to enter the corneal stroma and epithelium, is a serious complication, known as corneal hydrops, [84,85] which may require surgical treatment [86,87].

Although the corneal endothelium is generally unaffected in keratoconus, this issue is controversial [4]. While several studies found no endothelial change with disease progression [70,88–90], one study reported a slight increase in endothelial cell density in keratoconus [14], while two others reported a significant decrease in endothelial cell density, particularly in moderate to severe keratoconus [63,65,68].

5. Aetiology and pathogenesis

Understanding of the mechanism behind the development of keratoconus is still limited. There are no well-established animal models for the disease; mouse models have been developed, but mouse and human genomes are not organised in a similar pattern. Hence, research has mainly focused on clinical observations and donor corneal samples (extracted during a corneal graft operation) and hence are generally from more severe cases. Obtaining demographically matched, healthy corneas for comparison is also difficult and samples degrade rapidly after extraction. Keratoconus progresses as a combination of simultaneously occurring destructive and healing processes [76].

5.1. Genetics

Keratoconus has long been considered to have a genetic component, given its association with other genetic syndromes (such as Down's syndrome [91], Leber's congenital amaurosis [92,93], Ehlers-Danlos syndrome [94] and Noonan syndrome [95]), its prevalence in first-degree relatives [96–99] and occurrence in monozygotic twins [100,101]. It has been estimated that a relative of an individual with keratoconus has a 15 to 67 times greater risk of developing keratoconus than an individual with no family history of keratoconus [102]. Keratoconus follows an apparently autosomal dominant/recessive mode of inheritance in some families [103,104]. However, sporadic cases show no Mendelian patterns of inheritance [105], but computer-assisted corneal topography in parents of patients with keratoconus detects the disease in more family members than previously diagnosed, which affects familial analysis [99,106,107].

Loci on 73% (16 out of 22) of human autosomal chromosomes have been suggested to be involved in keratoconus and 59% of these could be considered to show statistically significant associations [108]. To date, only a single keratoconus locus (5q21.2) has been replicated across multiple linkage studies [103,109], suggesting that it could be a polygenic disease (two or more affected genes are required for keratoconus to develop). Detailed studies of the key candidate genes (VSX1 and SOD1) and others [110] have been inconclusive, leading to the hypothesis that mutations, in the presence of other gene variants (referred to as modifier genes), are required to elicit keratoconic traits [109]. This supports the notion that keratoconus is a multifactorial disease [111] and that multiple genetic factors, together with other factors influence the development of keratoconus traits. Keratoconus may even be a range of diseases that have relatively similar manifestations [96].

5.2. Cellular biochemistry

To date, 117 proteins and protein classes have been implicated in the pathophysiology of keratoconus [3]. Differential expression of several corneal proteins results in changes in the structural integrity and morphology of the keratoconic cornea, through altering its collagen content and keratocyte apoptosis and necrosis in the stroma [112,113]. Oxidative stress markers and antioxidants are dysregulated in keratoconus, involving an imbalance of redox homeostasis in tears, cornea, aqueous humour and blood [114]. Keratoconus is associated with an overall increase in oxidative stress markers, particularly in reactive oxygen and nitrogen species and malondialdehyde. It is also associated

with an overall decrease in antioxidants, including a significant decrease in total antioxidant capacity/status, aldehyde/NADPH dehydrogenase, lactoferrin/transferrin/albumin and selenium/zinc. Oxidative stress markers are higher in tears and in the cornea of keratoconic than in the aqueous humour, and antioxidants were decreased in tears, aqueous humour and blood. Oxidative stress markers increased in stromal cells and antioxidants decreased in endothelium [114]. The disease is associated with an up regulation of degradative enzymes and inhibition of the activity of protease inhibitors [115], resulting in corneal thinning [112]. The increase of proteinase activity results in the induction of a degradative process in the cornea [115–117].

In the keratoconic cornea, there is a gradient of damage between the centre of the cone (which shows the greatest level of damage) and the periphery [76]. At a cellular level, penetration of fine keratocyte processes into the anterior limiting membrane have been observed in localised regions, generally in association with localised indentation of the basal epithelium, often where nerves penetrate between the stroma and epithelium. Increased levels of lysosomal enzymes (Cathepsin B and G) have been measured in these stromal keratocytes in the disrupted regions, which have been hypothesised as the driving force to structural damage to the anterior limiting membrane and underlying stroma [77]. Physical stresses from the intraocular pressure and eye rubbing are likely to exacerbate this degradation. Nerve associated Schwann cells express higher levels of Cathepsin B and G in keratoconic corneas and these enzymes are known to be active in other disease neural tissues [77].

5.3. Biomechanical factors

The degeneration of the proteoglycans around the stromal collagen fibrils in keratoconic corneas leads to breakage of, and degeneration of the microfibrils within, collagen fibrils [118]. These changes result in a reduction of the diameter of the collagen fibrils, and the reduced number and different distribution of lamellae, composed of these degenerated fibrils, are biomechanically weak and prone to disorganisation and undulation [80,118,119]; hence, these changes eventually result in alteration of the curvature of the cornea ultimately leading to cone formation. Polymorphisms of the antioxidant enzymes (catalase and glutathione peroxidase) have been shown to act as independent predictors of the severity of keratoconus, perhaps due to mechanical insult to the cornea, highlighting the role of oxidative stress in the pathogenesis of the disease [120]. Keratoconic corneas have decreased levels of aldehyde dehydrogenase Class 3 [121] and superoxide dismutase enzymes [122]. Both enzymes play important roles in the reactive oxygen processes of different species. The reactive oxygen accumulation causes cytotoxic deposition of malondialdehyde and peroxynitrites, which could potentially damage corneal tissue [114,123–125].

Matrix stiffness, which regulates the physiology of the cells in tissues throughout the body and plays an important role in maintaining their homeostasis, is altered in keratoconus. Additionally, it has been reported to regulate cell division, proliferation, migration, extracellular uptake, and various other physiological processes. There is a connection between endocytosis and matrix stiffness in keratoconus which may explain the link between mechanical and biochemical factors [126].

Although rigid contact lens wear has also been associated with keratoconus development [127], perhaps as a result of altered cell morphology following lens wear [128], it seems unlikely that contact lens wear could trigger the development of keratoconus.

5.4. Risk factors

Several environmental and familial factors are associated with an increased risk of developing keratoconus (Table 2). Allergy and atopy have long been associated with keratoconus, with the majority of studies showing a positive association and the reported prevalence being 11 to 30% [129]. Another strongly associated risk factor in the pathogenesis

Table 2

Environmental and familial risk factors for keratoconus [108,130].

Factor	Relative Risk
Family history of keratoconus	6.4
Eye rubbing	3.1
Eczema	3.0
Asthma	1.9
Allergy	1.4

of keratoconus is eye rubbing [130]. A common mediator to these major risk factors is Immunoglobulin E, which has been identified as elevated, even in some patients with keratoconus without inflammatory symptoms and signs [129]. In keratoconus patients, the incidence of elevated levels of total serum Immunoglobulin E was between 52% and 59% for raised serum specific Immunoglobulin E levels [131]. A recent systematic review and meta-analysis, in which 3996 articles were retrieved, of which 29 were analyzed including 7,158,241 participants from 15 countries, identified the odds ratios (OR) of having keratoconus to be 3.09 times (95% CI: 2.17–4.00) for those reporting eye rubbing, 1.42 times (95% CI: 1.06–1.79) for those with allergy, 1.94 times (95% CI: 1.30–2.58) for those with asthma and 2.95 times for those with eczema (95% CI: 1.30–4.59); however, the odds ratio for those with a family history of keratoconus was 6.42 (95% CI: 2.59–10.24), showing the significant influence of genetics [130]. One other recent study reported eye rubbing (odds ratio: 4.93), family history of keratoconus (odds ratio: 25.52) and parental consanguinity (odds ratio: 2.89) to be significant risk factors for keratoconus [98], whereas another study also reported eye rubbing (odds ratio: 3.53,) and consanguineous marriage (odds ratio: 12.87) to be independent risk factors for keratoconus [57]. Another recent study, which involved an analysis of 2,051 keratoconus cases and 12,306 matched controls, identified novel associations between keratoconus and Hashimoto's thyroiditis (OR = 2.89; 95% CI: 1.41 to 5.94) and inflammatory skin conditions (OR = 2.20; 95% CI: 1.37 to 3.53), and confirmed known associations between keratoconus and atopic conditions, including allergic rash (OR = 3.00; 95% CI: 1.03 to 8.79), asthma and bronchial hyperresponsiveness (OR = 2.51; 95% CI: 1.63 to 3.84), and allergic rhinitis (OR = 2.20; 95% CI: 1.39 to 3.49) [132]. These latter results indicate that keratoconus appears positively associated with multiple immune-mediated diseases, which provides an argument that systemic inflammatory responses may influence its onset.

6. Clinical features

Keratoconus usually develops in the second and third decade decades of life and progresses until the fourth decade, when it stabilises [27–29], although it can develop earlier [50,53,55,56] or later in life [39,44,46,47] (Table 3). The condition typically affects both eyes, although with different degrees of severity, and it has well-established signs and symptoms, although there is no clear consensus regarding the signs and symptoms associated with early keratoconus (Table 3) [1,10,133]. The early stages of the disease are commonly referred to as subclinical or form-fruste keratoconus, although there is a lack of unified criteria in the use of these two terms [134]. Subclinical keratoconus typically refers to an eye with topographic signs of keratoconus (or suspicious topographic findings) with normal corneal slit-lamp findings and keratoconus in the fellow eye [134]. Form fruste keratoconus typically refers to an eye with normal topography, normal corneal slit-lamp findings, and keratoconus in the fellow eye [134]. It has been recently reported that eyes with form fruste keratoconus have an increased central epithelial to stromal thickness ratio and asymmetric superior-nasal epithelial thinning, whereas keratometric and corneal volumetric alterations are more prominent in subclinical keratoconus [135]. Characteristics of eyes with subclinical keratoconus also include an asymmetrically displaced anterior and posterior corneal apex, corneal thinning, and loss of corneal volume [136].

Table 3
Signs and symptoms based on keratoconus severity. Of note is that the time course for the development of keratoconus signs and symptoms, and their association with disease severity are highly variable. VA, visual acuity; BCVA, best corrected visual acuity; D, dioptres.

Stage	Signs	Symptoms
1 – Sub-clinical	Suspicious topography; normal slit-lamp findings; and ~ 6/6 VA achievable with spectacle correction.	None or slight blurring of vision
2 – Early	‘Scissor reflex’; Charlotoux’s oil droplet reflex; mild, localised corneal steepening and thinning; increasing keratometric differences between inferior and superior cornea; increases in corneal aberrations (particularly coma-like aberrations); mild changes in refractive error; and reduction of spectacle BCVA. Those of stage 2 (normally of greater severity) plus: significant corneal thinning; Vogt’s striae; Fleischer’s ring; < 6/6 spectacle BCVA, but ~ 6/6 spectacle BCVA with contact lenses; increased refractive changes; increased visibility of corneal nerves; corneal scarring and opacities normally absent.	Mild blurring or slightly distorted vision
3 – Moderate	Those of stage 3 (normally of greater severity) plus: severe corneal thinning and steepening (>55D); corneal scarring; < 6/7.5 VA with contact lens correction; Rizzuti’s sign; Munson’s sign; corneal opacities; and corneal hydrops;	Moderate blurring and distorted vision
4 – Severe		Severe blurring and distorted vision, and monocular polyopia (typically reported as ‘ghost’ images)

Detecting the earliest stages of keratoconus remains a challenge, although it is particularly important as it can lead to better management and long-term prognosis. In its early stages, the symptoms of keratoconus can mimic the symptoms of simple refractive errors, and if a corrected visual acuity of 6/6 (i.e., 20/20) is achieved without obvious clinical signs of keratoconus, detection of the disease is unlikely unless corneal imaging is performed. Particular attention should be given to the results of the axial curvature map from the corneal topographer to depict any patterns typically associated with keratoconus [135]. As keratoconus progresses, symptoms can include mild blurring or slightly distorted vision along with a reduction in spectacle best corrected visual acuity. Other common signs preceding ectasia include mild, localised corneal steepening, an increasing difference between the inferior and superior corneal curvature, and increasing anterior corneal aberrations, particularly coma-like aberrations [2,135]. Corneal thinning typically occurs in the central or paracentral cornea, often in the inferior-temporal corneal quadrant [9], although occasional superior localisations have also been reported [48,137–139]. Nipple and oval cones located in the central or paracentral cornea are most common, whilst globus cones and peripherally located cones are rare [140].

Several clinical signs are associated with keratoconus. The ‘scissor reflex’ is observed during retinoscopy assessment. Charlotoux’s oil droplet reflex is also commonly seen in early keratoconus using retroillumination with a dilated pupil, which produces a dark, round shadow in the corneal midperiphery [141]. Fleischer’s ring and Vogt’s striae can be observed as the disease severity increases (Table 3). Fleischer’s ring is believed to be a subepithelial deposition of iron oxide hemosiderin within the posterior limiting lamina membrane that manifests as yellow–brown to olive-green pigmentation in an arc or ring shape around the base of the cone [142]. Vogt’s striae may be seen as fine as well as relatively thick, vertical, stress lines within the posterior stroma and posterior limiting lamina due to stretching and thinning of the cornea, that disappear while exerting gentle pressure to the globe, although they may also have a fanlike appearance around the base of the cone. Occasionally, striae can be observed without the use of a slit lamp. Fleischer’s ring and Vogt’s striae are observed in one or both eyes in 86% and 65%, respectively of patients with keratoconus [143,144] and it has been proposed that the presence of these two signs may confirm diagnosis in borderline cases [145]. Superficial and deep corneal opacities and increased visibility of corneal nerves are also commonly observed in keratoconus [6]. Although these signs can manifest at any point during disease development and progression, the more advanced the disease the greater the likelihood that Vogt’s striae, Fleischer’s ring, and/or corneal scarring will be present [7].

Epithelial or subepithelial corneal scarring is also a characteristic sign of keratoconus (Fig. 3), and is more commonly observed in patients with: a younger age at diagnosis; corneal staining; greater corneal curvature (i.e., >55 D or steeper than 6.13 mm); and who wear contact

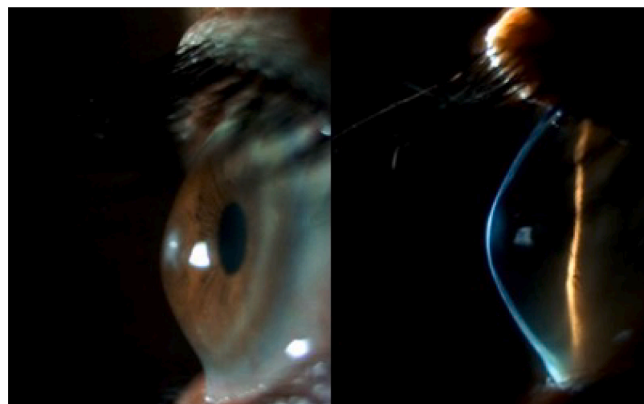


Fig. 3. Slit-lamp images showing corneal scarring.

lenses [146]. This slit lamp finding also corresponds with stromal haze and hyperreflectivity as observed using confocal microscopy [67]. In severe cases, highly pronounced cones can create a V-shaped deformation of the lower eyelid during downgaze, known as Munson's sign [141,147]. Rizzuti's sign, a bright reflection of the nasal area of the limbus when light is directed to the temporal limbal area, is another sign frequently observed in advanced stages [148]. Severe keratoconus may result in corneal hydrops, characterised by marked corneal oedema due to a break in the posterior limiting lamina, which allows aqueous to enter the corneal stroma and epithelium. Although hydrops can be self-limiting within ~ 3 months, acute cases may require corneal suturing or intracameral gas injection depending upon the severity [149]. Corneal hydrops can result in central vision-impairing scar tissue and corneal irregularity, necessitating in many cases the need for scleral contact lenses to achieve functional vision [150], and in some cases corneal transplantation [84]. Significant risk factors independently associated with the development of hydrops in keratoconus (using multivariate analysis to address co-dependencies) include vernal keratoconjunctivitis (adjusted odds ratio (AOR) 15.00x), asthma (AOR 4.92x), and visual acuity in the worse eye (i.e. disease severity, AOR 4.11x) [151].

Corneal protrusion, the scissors reflex, corneal thinning, Fleischer's ring, and prominent corneal nerve fibres are the most prevalent clinical signs in keratoconus (Fig. 4), with all signs observed in over 50% of patients with keratoconus [141]. However, the time course of the development of these clinical signs and their association with disease severity are highly variable. Although identifying clinical symptoms and slit-lamp findings in keratoconus are important, corneal topography is currently the primary diagnostic tool for keratoconus detection [2]. In incipient cases, however, the use of a single parameter as a diagnostic factor is not sufficiently accurate, and pachymetry and corneal aberration data are now also commonly used in conjunction with corneal topography to aid early diagnosis and monitor progression and treatment outcomes [2,152]. In addition to corneal topography that provides two-dimensional imaging of the corneal surface based on curvature data, corneal tomography is a three-dimensional imaging technique that characterises the anterior/posterior corneal surfaces based on curvature data of the anterior surface and elevation data of both the anterior and posterior corneal surfaces, along with corneal thickness distribution [153], which have found critical to enhance the sensitivity and

specificity for detecting corneal ectasia in comparison to corneal topography [133,154]. Furthermore, various machine learning algorithms have been developed using routinely collected clinical parameters that can assist in the objective detection of early forms of the disease [2,155].

7. Detection

The early detection of keratoconus can lead to improved patient outcomes though more frequent review to monitor disease progression and timely interventions when indicated (e.g., corneal collagen cross-linking), ultimately reducing the need for corneal transplantation. Consequently, most research concerning the detection of keratoconus has focused on identifying the first clinical signs of corneal disease. For example, differentiating between "form fruste keratoconus" (no corneal topography or slit lamp abnormalities, but keratoconus in the fellow eye) or "keratoconus suspects" (preclinical or subclinical keratoconus, typically defined as a cornea with no detectable abnormalities based on slit lamp examination, but inferior corneal steepening/asymmetry with unaffected visual acuity) from non-keratoconic eyes [156]. Additionally, efforts have also been made to obtain consensus from a panel of ophthalmology experts from around the world that resulted in definitions, statements, and recommendations for the diagnosis and management of keratoconus and other ectatic diseases that should help eye care providers around the world to adopt best practices for these often visually debilitating conditions [133]. Studies assessing the diagnostic utility of a particular corneal metric typically report the sensitivity (the ability to correctly identify eyes with keratoconus), the specificity (the ability to correctly identify eyes without keratoconus), and the threshold beyond which a cornea would be considered keratoconic. Importantly, there is currently no single metric that can unequivocally differentiate emerging disease from normal corneal data, so a diagnosis of keratoconus must consider a range of corneal parameters, including their interocular asymmetry. Scoring indices that combine several different corneal parameters have been developed to improve diagnostic accuracy. This section reviews emerging methods of keratoconus detection over the past decade.

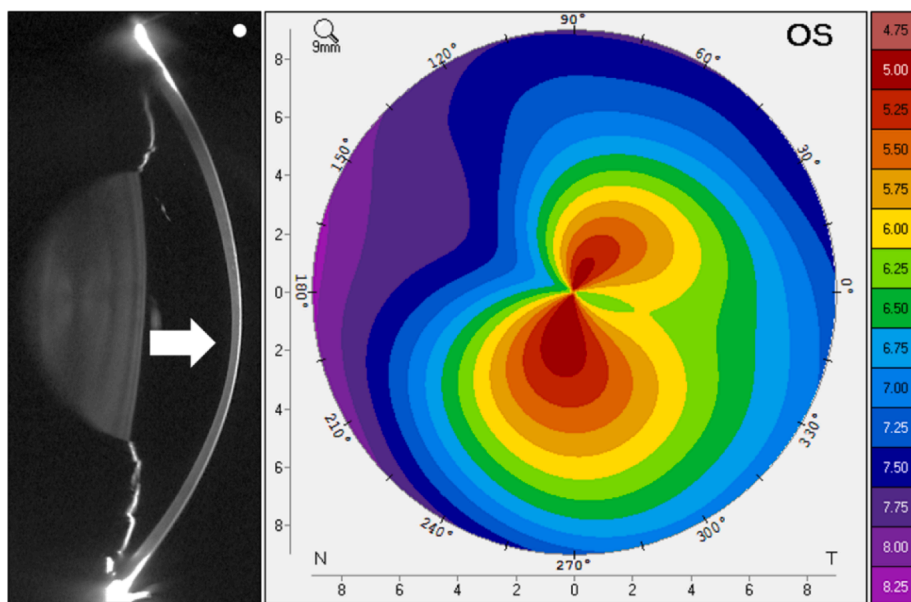


Fig. 4. Vertical Scheimpflug image (left) and anterior axial curvature map (right) of a cornea with advanced keratoconus; mean central anterior keratometry 56 D, anterior corneal astigmatism 11.8 D, thinnest corneal pachymetry 381 μm . The white dot on the top left indicates the superior aspect of the image and the arrow indicates the region of central-inferior corneal thinning.

7.1. Corneal morphology

7.1.1. Thickness profile

Since the advent of high-resolution anterior segment optical coherence tomography (OCT) imaging, numerous studies have investigated the thickness profile of individual corneal layers in keratoconus. Keratoconic eyes typically display epithelial thinning at the corneal apex (cone), surrounded by an annulus of epithelial thickening, thought to be an epithelial remodelling response in order to provide a smooth optical surface over an increasingly irregular and steepening anterior stroma [157–159]. A reduction in epithelial basal cell density may also lead to the thinning and fragmentation of the anterior limiting lamina [72], which also appears to be indicative of early keratoconus [160].

The stroma of keratoconic eyes is also typically thinner infero-temporally (correlating with the average cone location) and thicker superior-temporally compared to non-keratoconic eyes with astigmatism; however, these regional variations are more apparent in the epithelial profile [161], even in subclinical keratoconus [162]. For example, Li et al [162] reported that an epithelial thickness metric has 96% sensitivity and 100% specificity for distinguishing subclinical keratoconus from normal eyes compared to stromal (92%, 80%) and total corneal thickness (92%, 92%) metrics. This approach using an epithelial thickness metric derived from OCT imaging appears to be more suitable for detecting subclinical keratoconus compared to numerous studies using central or minimum total corneal thickness data [2].

A limitation of detecting keratoconus using corneal epithelial thickness profiling is that image segmentation can be difficult in the presence of changes in the anterior limiting lamina and thickness measurements are typically less reliable in keratoconic compared to non-keratoconic corneas [163,164]. Epithelial thickness metrics should still be considered in conjunction with other clinical measures in the diagnosis of keratoconus [165].

7.1.2. Tomographic indices

Although anterior corneal curvature and anterior and posterior astigmatism are significantly elevated in keratoconus compared to non-keratoconic eyes, these parameters are not particularly useful in the differentiation of subclinical keratoconus from normal eyes [2]. Since changes in the posterior corneal surface may be one of the first clinically detectable signs of keratoconus [166–168] numerous studies have investigated the utility of posterior corneal metrics. These metrics

cannot be obtained from traditional reflection-based topographers, but are measured using Scheimpflug imaging, slit scanning tomography, or optical coherence tomography. One of the most commonly used metrics is the posterior corneal elevation (i.e., how the elevation of the posterior cornea deviates relative to a reference body such as a sphere or ellipse) [169] (Fig. 5). The utility of this metric for identifying emerging keratoconus varies with respect to the analysis diameter and reference body used (Table 4). A panel of ophthalmology experts from around the world have proposed that posterior corneal elevations abnormalities must be present to aid in the diagnosis of early or subclinical keratoconus [133]. Fig. 6.

7.1.3. Other corneal morphological characteristics

7.1.3.1. Corneal surface area. The ratio of anterior and posterior corneal surface areas (derived from OCT or Scheimpflug imaging) is significantly decreased in keratoconic compared to non-keratoconic eyes [175–177], potentially due to pathological changes in both

Table 4

Table summarising all studies which provided the sensitivity, specificity, and a threshold value of posterior corneal elevation to differentiate form fruste or suspected keratoconus from non-keratoconic eyes. BFS, best fit sphere; BFTA, best-fit toric and aspheric body/ellipsoid; E-BFS, enhanced best fit sphere (3.5 mm diameter removed centred on thinnest point); MEL, maximum elevation; TEL, elevation at thinnest corneal point.

Author, Year	Reference body (diameter, mm)	Threshold (μm)	Specificity (%)	Sensitivity (%)
de Sanctis et al, 2013 [170]	BFS (9)	27	87	73
	E-BFS (8)	12	84	60
Muftuoglu et al, 2013 [171]	BFS (9)	9	59	67
	BFTA (8) MEL	14	55	51
Sideroudi et al, 2014 [173]	BFTA (8) MEL	13	80	82
	BFS (8) MEL	12	86	83
Golan et al, 2018 [174]	BFS (8) TEL	10	97	70
	BFTA (8) MEL	9	79	91
	BFTA (8) TEL	5	97	82
	BFTA (8) MEL	11.5	85	80

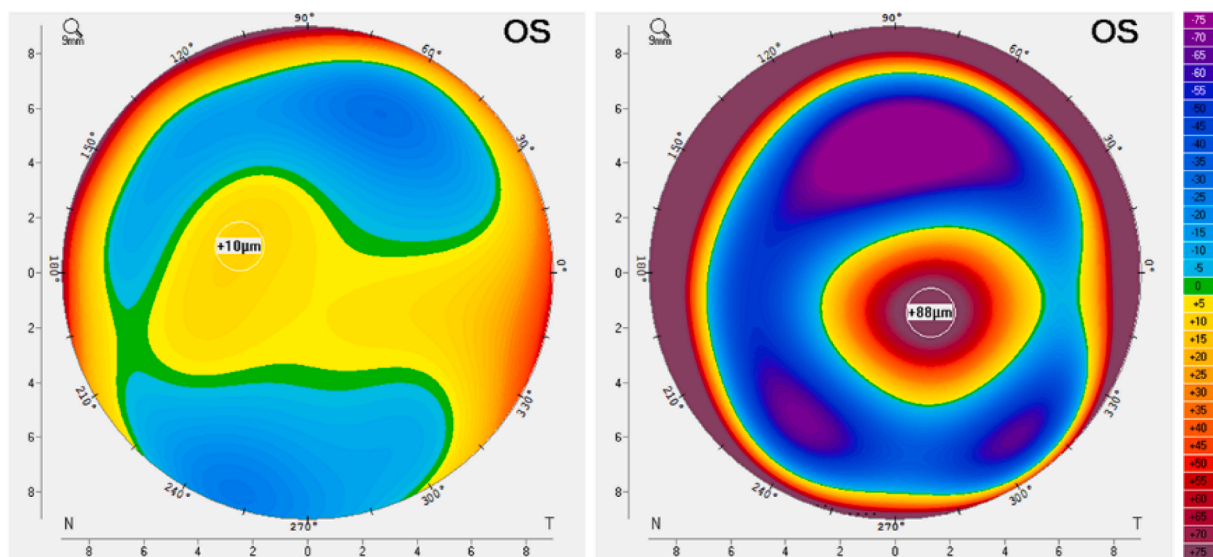


Fig. 5. Posterior corneal elevation maps relative to the best sphere reference body (8 mm diameter) for a non-keratoconic (left, maximum elevation 10 μm) and a keratoconic eye (right, maximum elevation 88 μm). For this metric, a maximum elevation $>12 \mu\text{m}$ is typically indicative of keratoconus (Table 3).

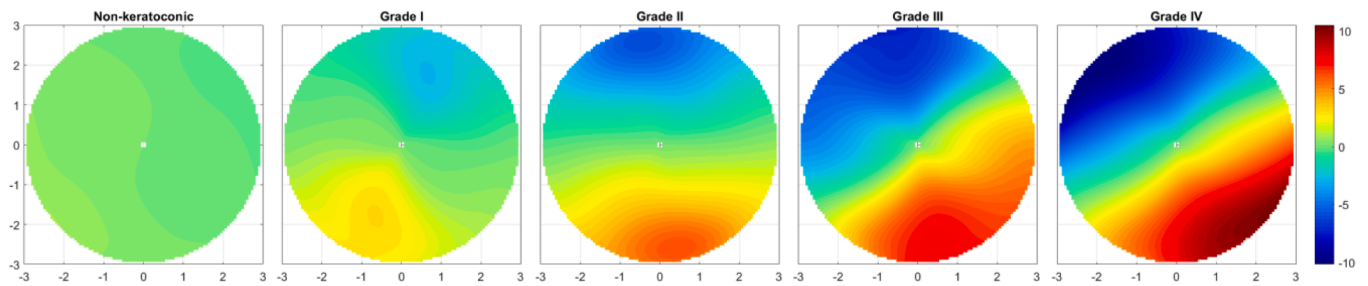


Fig. 6. Refractive power maps derived from the anterior corneal higher order aberration “coma-like” data (Zernike radial orders 3, 5, and 7) demonstrating the increase in vertical coma with increasing severity of keratoconus (Alio-Shabayek [235] classification system). Warmer (i.e., red) and cooler (i.e., blue) colours represent increased and decreased corneal power. The coma-like RMS values across a 6 mm pupil are: non-keratoconic = 0.25 μm ; Grade I = 1.50 μm ; Grade II = 2.52 μm ; Grade III = 3.84 μm ; and Grade IV = 4.60 μm . (For interpretation of the references to colour in this figure legend, the reader is referred to the web version of this article.)

anterior and posterior corneal surfaces and appears to be a useful metric to differentiate form fruste keratoconus from non-keratoconic eyes (specificity 96% and sensitivity 92%) [178].

7.1.3.2. Corneal light intensity distribution. Recently, the light intensity distribution derived from Scheimpflug imaging has been modelled to evaluate microscopic corneal properties following contact lens wear [179], and as a novel approach to differentiate keratoconic and non-keratoconic corneas when imaged during mechanical stimulation [180,181]. The statistical parameters derived from these analyses have good sensitivity (76–96%) and specificity (76–88%) for detecting keratoconus, which increases when combined with measures of central corneal thickness (sensitivity 100%, specificity 95–100%) [181]. The same image analysis approach has been used to identify the base of the cone [182]; however, further research is required to assess if this technique has any clinical utility in the early detecting keratoconus or monitoring disease progression.

7.1.3.3. Artificial intelligence. Over the past decade, different approaches (machine and deep learning algorithms) have been utilised in an attempt to automate the detection and classification of keratoconus based on a wide range of corneal parameters [183,184]. In general, algorithms designed to differentiate manifest keratoconus from non-keratoconic eyes using corneal topography or tomography [185–191] or OCT data [192–194] are highly reliable with specificity and sensitivity scores typically >95%. Several techniques have also shown excellent potential to differentiate form fruste or suspected keratoconus from normal eyes [155,185,188,189,194–196] or manifest keratoconus from suspected keratoconus [191,197]. In the future, longitudinal corneal data may be used to develop algorithms to predict future disease progression to identify eyes that may benefit from more frequent review or early intervention.

7.2. Optical

7.2.1. Anterior corneal higher order aberrations

Anterior corneal higher order aberration (HOA) metrics, derived from the corneal elevation profile, that are particularly useful in the detection of keratoconus (specifically differentiating normal eyes from sub-clinical, form fruste, or emerging keratoconus) include; vertical coma (C(3,-1)), the root mean square error (RMS) of horizontal and vertical coma, and the RMS of 3rd radial order (which includes vertical coma) [198–203]. Table 5 summarises the specificity and sensitivity of these metrics for specific thresholds. For a 6 mm corneal diameter, vertical coma < \sim -0.17 μm , RMS coma > \sim 0.275 μm , and 3rd order RMS > \sim 1.80 μm , are indicative of keratoconus. The ability to discriminate between healthy eyes and sub-clinical keratoconus is improved when anterior corneal HOA metrics are considered together with other corneal parameters such as pachymetry and posterior corneal aberrations [198].

7.2.2. Posterior corneal higher order aberrations

Posterior keratoconus is a rare corneal condition that affects only the posterior corneal surface [204,205]. However, in keratoconus that involves the anterior cornea, the internal ocular HOAs, that arise from the posterior corneal surface and crystalline lens, are also elevated in comparison to healthy controls [206–208]. This is due to changes in the posterior corneal surface [208] and can result in significant residual HOA (predominantly vertical coma) when the aberrations of the anterior corneal surface are effectively neutralised with the post-lens tear layer of a rigid contact lens [209]. Although posterior corneal HOA's increase considerably with moderate to advanced keratoconus compared to healthy controls, these data do not significantly enhance the ability to differentiate normal corneas from subclinical keratoconus compared to anterior corneal HOA data alone [201,207].

7.2.3. Total ocular higher order aberrations

Although the internal optics of the eye (the contribution of the posterior corneal surface and the crystalline lens) partially compensate

Table 5

Table summarising all studies which provided the sensitivity, specificity, and a threshold value of anterior corneal higher order aberration (HOA) metrics to differentiate normal and form fruste or suspected keratoconus.

Author, Year	HOAMetric	Threshold (μm)	Diameter (mm)	Specificity(%)	Sensitivity(%)
Gobbe & Guillon, 2005 [199]	Vertical coma	< -0.116	6	72	89
Bühren et al, 2007 [200]	Vertical coma	\leq -0.202	6	94	100
	Coma RMS	\geq 0.248	6	74	100
Bühren et al, 2010 [201]	Vertical coma	\leq -0.200	6	97	94
Saad & Gatinel, 2012 [198]	Vertical coma	< -0.095	5	78	71
	Coma RMS	> 0.157	5	80	71
Xu et al, 2017 [202]	3rd order RMS	> 1.852	6	78	68
Naderan et al, 2018 [203]	Vertical coma	< -0.180	6	64	68
	Coma RMS	> 0.305	6	73	55

for anterior corneal higher order aberrations (potentially more so in keratoconus [207]), several studies have shown that total ocular higher order aberrations can also be used to differentiate normal healthy eyes from sub-clinical keratoconus. Eyes with sub-clinical (form fruste) keratoconus typically display substantially more negative vertical coma and consequently elevated total ocular third order and higher order RMS values [203,209–211]. However, the ability to differentiate between healthy eyes and sub-clinical keratoconus is improved if the total wavefront is considered in combination with anterior corneal higher order aberration data [198,212]. As outlined above, this suggests that with respect to HOA, the contribution from the anterior corneal surface is the most important to detect subclinical keratoconus.

7.3. Corneal biomechanics

Over the past decade, interest in corneal biomechanics in relation to the detection of keratoconus has increased considerably due to the availability of instruments (e.g., Ocular Response Analyzer and CorVis Scheimpflug Technology) that can quantify *in-vivo* corneal viscoelastic properties based on its deformation response [2,213,214]. Since corneal biomechanical properties are altered in keratoconus (based on *in-vitro* analyses of donor corneas) [215–217], it has been hypothesised that biomechanical metrics may be a sensitive marker to detect sub-clinical keratoconus. However, while some biomechanical properties are partially related to corneal thickness [218] and are significantly altered following corneal surgery [219,220], there is limited evidence supporting the ability of these devices to differentiate normal eyes and those with subclinical or established keratoconus [221–225]. A constraint of current commercially available instrumentation is that only central corneal measurements can be obtained and are unlikely to align with the cone location or thinnest corneal point in keratoconus. Currently, *in-vivo* corneal biomechanical parameters are not a sensitive and reliable metric to differentiate normal eyes and sub-clinical keratoconus in isolation, but may be of use in multivariate modelling of disease progression [89] or in clinical practice following the development of more suitable metrics [226,227]. Emerging techniques such as optical coherence elastography [228] or the analysis of OCT speckle [229] may help to identify microstructural corneal changes allowing earlier detection of keratoconus.

8. Classification

The time course for the development of keratoconus signs and symptoms, and their association with disease severity are highly variable, making the classification of keratoconus severity challenging. Although several classification systems have been developed, which primarily rely on corneal morphology or changes such as corneal thinning, anterior and posterior corneal curvature, and cone position and shape [10], there is no clinically adequate classification system for keratoconus [133]. Assessment of optical and visual function, such as higher order aberrations, visual acuity and astigmatism is also commonly used for grading the severity of the disease [1]. Furthermore, some classification systems take into consideration keratoconus signs such as scars, Vogt's striae and Fleischer's ring [230]. In this section, the different classification systems currently available for assessing keratoconus severity based on (1) corneal morphology and disease evolution; (2) optical and visual function; and (3) descriptors of corneal shape (i.e., index-based systems), are discussed.

8.1. Morphological and disease evolution

The most commonly used classification systems based on morphological changes and disease evolution are:

Morphological (Buxton) classification [231] – This system classifies the disease based on the shape and position of the cone into oval, nipple and globe keratoconus: (1) in *oval* keratoconus the cone affects one or

two corneal quadrants, with the inferior quadrant being the most commonly affected location; (2) in *nipple* keratoconus the cone diameter is ≤ 5 mm and located in the central or paracentral cornea; and (3) in *globe* keratoconus the cone affects a large region of the anterior cornea ($>75\%$).

Keratometric classification [232] – This system categorises keratoconus into four grades based on the magnitude of the cornea's central corneal power: (1) *Mild* (<45 D); (2) *Moderate* (between 46 D and 52 D); (3) *Advanced* (between 53 D and 59 D); and (4) *Severe* (>59 D).

Hom's classification [10] – This system classifies keratoconus into four grades based on clinical signs: (A) *Preclinical* indicates that no keratoconus signs are detected; (B) *Mild* cases display mild corneal thinning and scissors reflex; (C) *Moderate* indicates poor visual quality and corneal thinning without corneal scarring; and (D) *Severe* keratoconus includes the presence of scars, unreliable refraction and severe corneal thinning.

Amsler-Krumeich classification [233] – This classification system, which seems to be the most frequently applied in clinical practice to classify keratoconus, uses a number of morphological and clinical features associated with keratoconus employed in the other classification systems described above (Table 6). It has been proposed, however, that this relatively old and outdated classification system fails to consider currently available clinical information and technological advances [133].

Keratoconus has been defined as progressive by some authors when one (or several) of the following changes occur in an interval of less than 1 year [234]:

- Increase in astigmatism ≥ 1.0 D
- Significant changes in the orientation of refractive axes
- Increase of 1.0 D or more in the optical power of the steepest corneal meridian
- Decrease of 25 μm or more in corneal thickness.

8.2. Optical and visual function

Changes associated with the development of keratoconus are not limited to anatomical and morphological alterations of the cornea; the disease is also associated with a significant decrease in optical quality resulting from increases in ocular aberrations and a loss of corneal transparency in some cases which can affect quality of life [236]. Classification systems which primarily consider optical and visual function are as follows:

Table 6

The Amsler-Krumeich [233] and Alio-Shabayek [235] classification systems for grading keratoconus severity. Coma-like RMS values refer to a 6 mm analysis diameter.

Amsler – Krumeich	Alio – Shabayek
Grade I	
Corneal steepening	No scars
Refraction > -5 D	Coma-like RMS 1.50 to 2.50 μm
Mean central K readings < 48 D	Mean central K readings < 48 D
Grade II	
No scars	No scars
Corneal thickness > 400 μm	Corneal thickness > 400 μm
Refraction > -8 D	Coma-like RMS > 2.50 to ≤ 3.50 μm
Mean central K readings < 53 D	Mean central K readings < 53 D
Grade III	
No scars	No scars
Corneal thickness > 300 μm	Corneal thickness > 300 μm
Refraction > -10 D	Coma-like RMS > 3.50 to ≤ 4.50 μm
Mean central K readings < 55 D	Mean central K readings < 55 D
Grade IV	
Central scarring	Central scarring
Corneal thickness > 200 μm	Corneal thickness > 200 μm
Not reliable refraction	Coma-like RMS > 4.50 μm
Mean central K readings > 55 D	Mean central K readings > 55 D

Alio-Shabayek [235] - This system, which is based on the Amsler-Krumeich classification, in addition to the assessment of keratometric readings and corneal thinning, takes into consideration corneal scarring and anterior corneal aberrations (i.e., RMS coma-like aberrations) to grade keratoconus severity (Table 6).

Keratoconus Severity Score (KSS) [230] - This system grades the severity of keratoconus from 0 (suspect) to 5 (severe) based on two corneal topographic indices (i.e., anterior corneal higher order aberration RMS error and mean central keratometry), the topographical pattern of keratoconus and slit-lamp clinical signs (i.e., Vogt's striae, corneal scarring and Fleischer's rings).

RETICS classification [237] - In addition to clinical signs and optical and visual function variables, this classification system also takes into consideration corneal biomechanical parameters (i.e., hysteresis and resistance factor).

Belin ABCD grading system [238] - Keratoconus severity is graded based on four variables: (A) anterior and posterior corneal radius; (B) curvature of the 3.0 mm central zone of the thinnest corneal location; (C) thinnest pachymetry; and (D) distance best corrected visual acuity. This grading system is included in the Oculus Pentacam Scheimpflug-based system (Oculus GmbH, Wetzlar, Germany).

8.3. Index-based systems

Several index-based systems for keratoconus detection have been included in various instruments of corneal shape assessment. These systems may include one or more variables for keratoconus detection and typically use cut-off values to allow differentiation between normal corneas, keratoconus suspects, and clinical keratoconus (Table 7).

9. Management and treatment

Keratoconus treatment varies depending on the disease severity and progression (see section 8. Classification). A keratoconus treatment flowchart has been developed by consensus from a panel of ophthalmology experts from around the world [140]. Typically, mild cases are treated with spectacles, moderate cases with contact lenses, while severe cases that cannot be managed with scleral contact lenses may require corneal surgery (Fig. 7). To prevent keratoconus progression, corneal cross-linking is recommended to increase the biomechanical stability and rigidity of the cornea, with early intervention normally warranted, which highlights the importance of early diagnosis and close monitoring. Keratoconus patients should be advised to avoid eye rubbing as the latter is commonly associated with keratoconus and may contribute to disease onset and progression [248]. Education and counselling appear to be the foundations for helping patients to control chronic habits of abnormal eye rubbing [249].

9.1. Mild keratoconus

Spectacles can only be used in mild cases of keratoconus, and often result in poor visual acuity [10]. Although spectacles are unable to compensate for irregular astigmatism, a novel design that considers the possible non-orthogonal positions of the eye's two optical power meridians has been proposed and has been shown to improve best-corrected spectacle acuity by 1–4 lines in two participants with mild keratoconus (refractive astigmatism ≤ 2.50 D) [250].

9.2. Moderate keratoconus

Currently, it is estimated that 90% of patients affected by corneal irregularity utilise contact lenses [251]. Several options are available for keratoconus management including gas permeable contact lenses (i.e., corneal, corneoscleral and scleral), piggyback systems (i.e., a rigid corneal lens fitted on top of a soft contact lens), soft contact lenses, and hybrid lenses (i.e., rigid centre and soft peripheral hydrophilic skirt)

Table 7

Index-based classification systems for keratoconus detection from normal cornea. Values greater than the proposed cut-off indicate suspected keratoconus. K, keratometry; Kmax, steepest anterior corneal curvature within the 3 mm central cornea; skewed radial axes (SRAX); D, dioptres; mm, millimetre.

Univariate Index Index [Reference]	Description	Cut-off	Specificity (%)	Sensitivity (%)
SIMK [197]	Simulated Keratometry is the difference in corneal power between the flattest (K1) and steepest (K2) corneal meridians	45.57 D	80	76
Q [239]	Anterior corneal asphericity (central 8 mm) describes how corneal curvature changes from the centre to the periphery.	-0.65	90	93
I-S [240]	Inferior-Superior index is the power difference between superior and inferior cornea	>2.33 D	95	89
SRI [241]	Surface Regularity Index describes corneal regularity within the 4.5 mm central cornea	>1.52	100	65
SAI [242]	Surface Asymmetry Index is the average corneal power from 128 corneal meridians	1.25	95	92
BCV [243]	Baiocchi Calossi Versaci index is the difference through the analysis of the coma, trefoil, and spherical aberration components	>0.524	99	97
Kmax/TP [244]	Max keratometry combined with thinnest pachymetry	>0.08	95	97
Multivariate Index				
KPI [240]	A combination of SimK1, SimK2, DSI, OSI, UPS, CSI, IAI and AA indices	>18.55	95	96
KSI [197]	Keratoconus Severity Index (also known as Smolek-Klyce) combines ten topographic indexes	>30%	93	93
KISA% [245]	A combination of K, SimK, I-S and SRAX	>60%	100	96
BADIII [246,247]	Based on anterior and posterior parameters, corneal thickness variables and Kmax	>2.6	61	100

[252,253]. Any of these lens types may be fitted to manage mild and moderate keratoconus, whereas scleral lenses might be the best option for successfully managing advanced cases.

9.2.1. Rigid contact lenses

Rigid lenses offer the greatest level of adaptability for managing keratoconus patients as it is only possible to reliably correct high levels of corneal irregular astigmatism through neutralization by the tear lens with this type of contact lens [144,254–256].

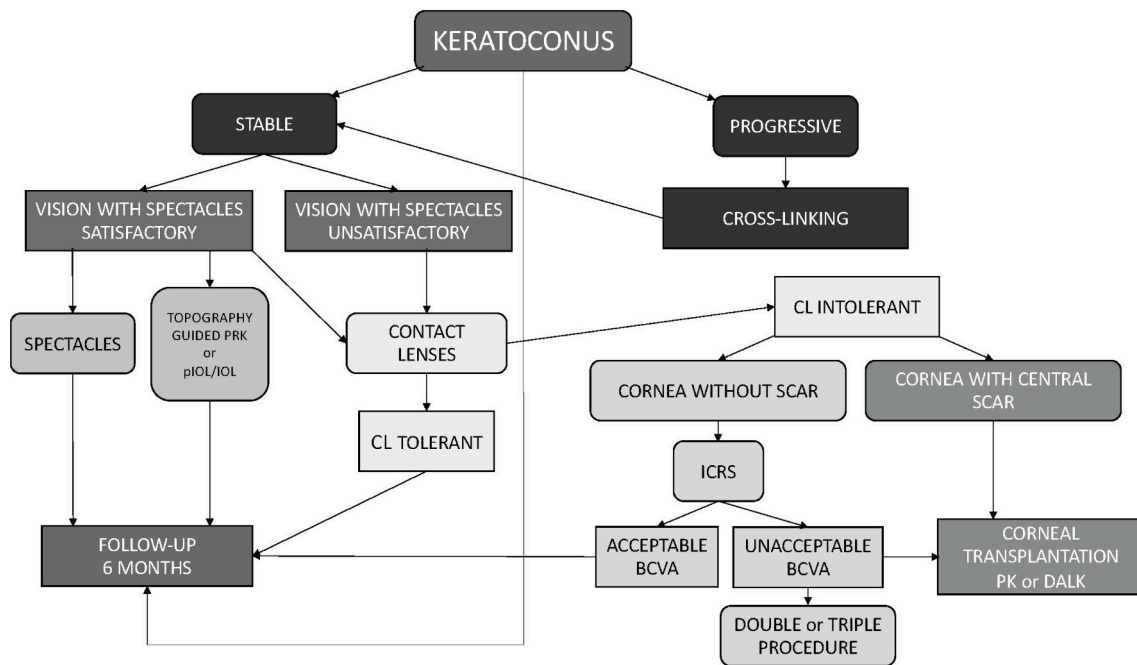


Fig. 7. Flowchart for keratoconus management. PRK, photorefractive keratectomy; pIOL, phakic and pseudophakic intraocular lens; IOL, intraocular lens; CL, contact lens; ICRS, intracorneal ring segments; BCVA, best-corrected visual acuity; PK, penetrating keratoplasty; DALK, deep anterior lamellar keratoplasty.

9.2.1.1. Rigid corneal contact lenses and piggyback systems. Three strategies have been traditionally used for fitting rigid corneal contact lenses in keratoconus including apical clearance, apical touch, and three-point touch [257,258]. A lens fitted using the apical clearance technique vaults the corneal apex and bears on the paracentral cornea. A lens fitted with apical touch exhibits light bearing on the central cornea, and can provide good vision. However, an increase in corneal scarring has been associated with this fitting technique [257,259]. The three-point touch technique, aims to provide lens support (corneal bearing) at three points along each meridian, including light apical touch and heavier paracentral corneal touch. A higher rate of optimal lens fits can be achieved using the three-point-touch approach (83%) compared to apical touch fittings (71%) [257]. Although no differences in comfort have been reported between these two fitting approaches [260,261], a greater level of corneal flattening is associated with the apical touch technique [258].

Currently, multiple keratoconus rigid corneal contact lens designs are commercially available, including multi-curve and aspherical designs with unique or variable back surface asphericity (quadrant-specific designs) [262], which have been shown to be successful in managing keratoconus patients [263]. Reverse geometry back surface contact lens designs have also been used in the optical correction of keratoconus; however, their use is limited since the anterior corneal surface in keratoconus is typically prolate [264].

Piggyback systems, which consists of a rigid corneal contact lens fitted over a soft contact lens, are also used for keratoconus management. The use of a soft contact lens can improve comfort and a rigid corneal contact lens centration and stability [265,266]. While low positive-powered soft contact lenses have traditionally been used in piggyback systems, a mild negative-powered soft contact lens can facilitate the fitting of a flatter and less minus powered rigid corneal contact lens, which may result in improved centration and movement and subsequently a reduction in spherical and coma-like aberrations. Oxygen transmissibility at the centre of the piggyback system may also be improved [267,268].

9.2.1.2. Corneoscleral and scleral lenses. Corneoscleral lenses are defined as any rigid contact lens with shared bearing between the peripheral cornea and conjunctiva overlying the sclera, irrespective of the

overall lens diameter [269]. The major advantages of these lens designs compared with rigid corneal lenses are improved comfort due to the reduced lens edge-eyelid interaction and enhanced stability and centration with larger optical zones for more consistent vision across a range of pupil diameters [270]. They are particularly useful for inferiorly located cones [271] or when other contact lens options (i.e., soft, corneal rigid, piggyback or hybrid lenses) fail to provide an acceptable visual outcome. As for rigid corneal lenses, corneoscleral designs can also be customised to improve lens centration and the overall fit (e.g., multicurve and aspheric designs, or toric/quadrant specific peripheral curves), and the location of corneal bearing varies with lens design and fitting philosophy [272]. Corneoscleral lenses display less movement upon blinking (up to ~ 0.5 mm) compared to rigid corneal lenses (1–2 mm), but more movement than scleral lens designs which settle back into the underlying conjunctival tissue over the course of the day [273]. Consequently, oxygen delivery is enhanced in corneoscleral designs compared to sealed scleral lenses, due to tear exchange and a thinner post-lens fluid reservoir which minimises corneal oedema [274,275]. Limbal compression must be avoided in corneoscleral designs since any insult at this anatomical location can potentially trigger a neovascular response [276]. Limited long-term data is available on corneoscleral lens designs in the management of keratoconus; however, significant improvements in higher order aberrations and visual acuity [277] compared to spectacles or habitual contact lens corrections have been reported for a range of corneal irregularities [272,277–279], with no apparent alteration in corneal biomechanics [280] or limbal stem cell health (based impression cytology and DNA analysis), after 12 months of lens wear [281].

Scleral lenses are defined as any rigid lens that vaults the cornea entirely, including the limbus, and rests upon the conjunctival tissue overlying the sclera [282]. They are particularly useful in the visual rehabilitation of advanced keratoconus when other lens modalities typically fail to achieve a physiologically acceptable fit due to central bearing or excessive lens decentration, and can delay or eliminate the need for a corneal graft in corneas with minimal central scarring [283–286]. Many scleral lens designs are available in prolate and oblate (i.e., reverse geometry) back surface lens designs, with a prolate profile recommended for keratoconic eyes to mimic the anterior corneal

contour. In recent years, with advances in anterior segment imaging, scleral lens prescribing has increased [287,288], including as a first lens of choice for healthy eyes with high regular astigmatism or ocular surface disease.

Despite increased lens stability and comfort of scleral lenses compared to rigid corneal or corneoscleral lenses, a disadvantage of scleral lenses is the increased potential for corneal hypoxia in healthy eyes [179,274,275,289–292], keratoconics [293], and following penetrating keratoplasty [294] due to reduced tear exchange [295–297] and the thicker central post-lens fluid reservoir (e.g. 200 μm compared to 20 μm in some corneoscleral designs). There is also a lens handling learning curve for patients during the first 6 months of lens wear [298] and ~30% of them experience regular fogging (i.e., fluid reservoir debris) [299,300] throughout the day that often necessitates lens removal and reapplication. Practitioners should also be aware that although scleral lenses vault the cornea, anterior corneal flattening can be observed immediately after lens removal [301–306]. Therefore, a period out of scleral lenses (in addition to rigid corneal lenses [307]) is required prior to corneal imaging to assess disease progression.

There has been some debate whether rigid corneal or scleral lenses provide superior visual outcomes [308,309], but only recently have well-controlled studies shed further light on this question. Bergmanson et al reported that 75% of keratoconics who had worn a range of different contact lens corrections previously and were successfully refitted into scleral lenses (75% of habitual contact corrections were corneal rigid, piggyback or hybrid lenses), reported a subjective improvement in their vision [310]. Using a cross-over study design, Kumar et al [311] compared the visual performance of a customised soft lens (Kerasoft), two rigid corneal lenses (a conventional design and Rose K2), and a scleral lens design (PROSE) in contact lens neophytes with keratoconus. All rigid lenses outperformed the customised soft lens for measures of distance visual acuity and contrast sensitivity, and the Rose K2 and scleral lens outperformed the conventional rigid corneal lens for more advanced keratoconus (steep K > 53 D). In contrast, in a randomised crossover trial [312] of successful and asymptomatic rigid corneal lens wearers (93% of eyes with keratoconus), no significant differences in objective measures of distance visual acuity, contrast sensitivity, or subjective reports of visual quality were observed between a rigid corneal lens (Rose K2, Menicon Co., Ltd, Nagoya, Japan) and scleral lens design (ZenLens, Bausch + Lomb, Bridgewater, NJ, USA). Residual aberrations that can arise from the posterior corneal surface in keratoconus during rigid lens wear can be minimised by incorporating an aspheric [313,314] or wavefront guided front surface design [315,316]. Scleral lenses provide an ideal platform for such front surface designs due to minimal movement upon blinking.

9.2.2. Soft contact lenses

In recent years, there have been significant developments in soft contact lens design for the correction of keratoconus [270,307]. Soft lenses are available in high spherical and toric powers for the correction of myopia and astigmatism in early keratoconus, decentred cones, and for patients with rigid lens intolerance [317,318].

Although soft contact lenses offer improved initial comfort compared to rigid lenses, they conform to the irregular corneal shape of the keratoconic cornea resulting in suboptimal visual correction. As such, soft contact lenses for keratoconus are designed with a thicker centre thickness (i.e., 0.2 mm to 0.6 mm) in an attempt to mask the irregular corneal shape and correct slight to moderate irregular astigmatism. The increased centre thickness decreases lens oxygen transmissibility; however, silicone hydrogel materials (e.g., Definitive 74, Contamac, UK) are now used for manufacturing these lenses.

Several soft toric contact lenses for keratoconus are currently available, including HydroCone® (Toris K, SeissLens, Switzerland) [318–320], KeraSoft® IC (UltraVision CLPL, UK) [321], and Rose K2 Soft (Menicon Co., Ltd, Japan), which show comparable clinical performance [311]. These lenses employ prism-ballast and peri-ballast

features as well as distinct differences in the centre and peripheral lens design to prevent undesirable lens rotation. The combination of all these features is reported to restore visual acuity to optimum levels by reducing irregular astigmatism from a range of aetiologies including keratoconus, trauma, and intrastromal ring surgery [320,322,323].

There has also been increasing interest in the development of aberration-controlled soft contact lenses for keratoconus [316,324–326] since wavefront sensors became commercially available about two decades ago [327]. Significant improvements in vision can theoretically be expected using contact lenses that correct both lower- and higher-order ocular aberrations [328]. However, lens flexure, translation, rotation, and tear layer effects associated with soft contact lens wear make the correction of higher order aberrations challenging. Since vertical coma is typically the most elevated higher-order aberration in keratoconus [209,235,329,330], contact lens designs that correct comatic aberrations have been a focus of numerous studies. Soft contact lenses designed to correct coma aberrations alone can significantly improve visual quality in keratoconus patients without correcting other higher-order aberrations [325,331–333]. Lens centration is a major factor that affects the clinical performance of aberration-controlled contact lenses, with visual performance decreasing when the decentration exceeds 0.5 mm [334]. More recently, a different approach has been proposed that utilises a standardised soft lens fitting set with several different vertically asymmetric powers and axes, in a similar manner to soft toric contact lens fitting [333,335]. Using this approach, a prototype soft contact lens design successfully corrected vertical coma and improved quality of vision in keratoconus patients [333]. Further enhancements to this approach included optimisation of the optic zone relative to the pupil centre, which resulted in further improvements of the correction of coma aberrations and overall visual performance [335]. Reverse geometry soft contact lens designs have also been used for keratoconus correction [251,321,331,336].

9.2.3. Hybrid contact lenses

A hybrid contact lens consists of a rigid corneal lens and a peripheral soft skirt to combine the optical benefits of corneal rigid lenses and the comfort provided by soft contact lenses. Early generation hybrid lenses were often associated with decreased comfort, complications due to the use of low oxygen permeability materials, and reduced durability of the GP/soft material interface [337–339]. Current hybrid lens designs, such as the ClearKone (Synergeyes, USA) or the Eyebrid (LCS laboratories, France), have overcome some of these issues, but are still not widely utilised in keratoconus management [340]. Their similar clinical performance in terms of visual quality and comfort, but higher cost in comparison with GP lenses may explain this limited uptake by eye care practitioners [341–343].

9.3. Severe keratoconus

Severe cases of keratoconus may be managed with scleral lenses, particularly when other lens modalities typically fail to achieve a physiologically acceptable fit [283–286]. If contact lens fitting fails, these cases may require corneal surgery, including corneal cross-linking, refractive surgery, corneal transplantation, or a combination of several refractive surgery procedures, for visual rehabilitation (Fig. 7). However, some surgical procedures are also used in mild to moderate cases of keratoconus, such as corneal cross-linking, to prevent further progression regardless of the severity, and certain types of refractive surgery which can be used in incipient cases as well. The different corneal surgery procedures for keratoconus management are summarised in the following section.

9.3.1. Surgical procedures

9.3.1.1. *Corneal cross-linking (CXL)*. Cross-linking increases the

biomechanical stability and rigidity of the cornea in an attempt to prevent keratoconus progression. The technique consists of the removal of central 6–7 mm of corneal epithelium followed by the subsequent application of 0.1% riboflavin solution and corneal radiation of ultraviolet-A light at 370 nm [344–346]. Ultraviolet-A radiation activates riboflavin leading to the formation of covalent bonds between collagen fibrils and the corneal stroma and an intense process of apoptosis of keratocytes in the anterior stroma [347]. The irradiation at the corneal endothelium, crystalline lens and retina is significantly smaller than the damage threshold [348]. This technique is contraindicated in corneas < 400 µm in central thickness as it may cause toxic reactions in the corneal endothelium [349,350].

Conventional CXL treatment involves removal of the corneal epithelium prior to riboflavin application and ultraviolet radiation (i.e., “epi-off” CXL). A number of long-term studies have demonstrated that, on average, epi-off CXL typically flattens the central cornea, improves visual quality and reduces cone progression [351–353]. As such, this surgical intervention is the first treatment of choice for progressive keratoconus patients [354], although clinical outcomes vary significantly from patient to patient [354–357]. This surgical procedure was found to be safe and effective for keratoconus in children and adolescents as evaluated post-operatively for periods ranging from 1 to 3 years [358–361], with similar initial efficacy as in adults [362], particularly in terms of improvement in visual and topographic outcomes following the first year of treatment [358]. Patients undergoing CXL typically still require contact lens correction following surgery [363]. More recently, several methods of “epi-on” (i.e., transepithelial) CXL have been proposed as keeping the corneal epithelium intact is likely to be less painful and may help avoid epi-off CXL-associated adverse events. Although transepithelial methods are gaining popularity, epi-off CXL has been shown to provide a better regularisation of the corneal surface and an improvement of HOAs in comparison with epi-on CXL [364]. A study investigated the 1-year outcomes of using 8 different combinations of CXL techniques for treating keratoconus, including 2 different CXL techniques (i.e., epi-on or epi-off), 7 riboflavin formulations, and 2 ultraviolet-A protocols (i.e., conventional 3 mW/cm or accelerated 9 mW/cm), in 670 eyes of 461 patients with progressive keratoconus [365]. Patients treated using the Dresden protocol were used as the reference group. Epi-on CXL, the use of Meran riboflavin, and applying the accelerated irradiation protocol appeared to be associated with reduced efficacy regarding controlling keratoconus progression, with one-third of cases treated using epi-on CXL required re-treatment. Corneal cross-linking has also been used successfully in combination with corneal ring segments and other surgical techniques [366–371].

9.3.1.2. Refractive surgery. Various refractive surgery interventions have been used for keratoconus management, with phakic lens implantation and photorefractive keratectomy (PRK), being the two most widely studied [372,373]. These techniques are contraindicated in progressive keratoconus and are performed when the condition stabilises. Refractive surgery techniques for keratoconus management may be classified into: (1) corneal, which includes excimer laser surgery, intracorneal ring segments, radial keratotomy and thermal therapy; (2) intraocular, including phakic and pseudophakic intraocular lenses; and (3) combinations of these procedures.

9.3.1.2.1. Corneal. Photorefractive keratectomy (PRK) uses an excimer laser to permanently modify the shape of the anterior central cornea by removing a small section of stromal tissue by vaporisation. Results in keratoconic eyes have been moderately successful, with some studies observing a significant reduction in cone evolution in incipient cases [374], as well as improved visual acuity and a reduction in higher-order aberrations [375,376]. PRK is usually performed in combination with CXL. A recent study which assessed the clinical outcomes of the use of topography/wavefront-guided PRK using a new high-definition aberrometer (iD2 system) in combination with CXL in mild to

moderate keratoconus reported a significant improvement in corneal shape regularity and visual and refractive outcome post- vs. pre-operatively [369].

Intracorneal ring segments (ICRS) were initially developed to treat low myopia [377], but have now evolved as a treatment for mild to moderate keratoconus. This surgical intervention is indicated in transparent corneas with a minimum thickness of 450 µm at the site of incision [378,379] and involves the implantation of one or two segments of polymethacrylate material into the corneal stroma to reshape the irregular surface. This can lead to an improvement in uncorrected and corrected visual acuity [379,380], a reduction in high-order corneal aberrations [381], and a more regular corneal shape that facilitates the fitting of contact lenses [382]. This surgical intervention may prevent or delay the need for corneal transplantation [380], and in combination with CXL can reduce anterior corneal higher-order comatic aberrations [370]. Although ICRS implantation can corneal curvature and improve visual acuity irrespective of the patient’s age, this technique does not seem to stabilise the disease progression, particularly in young patients with more aggressive keratoconus [353].

Other refractive surgery techniques used in the past for the treatment of keratoconus include radial keratotomy [383,384] and thermal therapy [385–389]; however, they are no longer commonly used due to their limited success rate.

9.3.1.2.2. Toric intraocular lens implantation (IOL). Phakic and pseudophakic intraocular lens implantation for the treatment of keratoconus is usually performed in conjunction with other corneal refractive surgery methods, such as corneal rings or keratoplasty [234]. The combination of these techniques, which are typically used to correct high levels of astigmatism in intolerant contact lens wearers, has been reported to improve visual acuity [390–392]. Of interest, however, is that toric IOLs should only be considered in mild-moderate cases of stable keratoconus with low levels of irregular corneal astigmatism, when the patient has satisfactory visual acuity with spectacles (i.e. patients who are highly unlikely to require rigid corneal or scleral contact lens correction following cataract surgery to improve vision) [393].

9.3.1.2.3. Combined procedures. The aforementioned surgical techniques can be used in combination for keratoconus treatment, including double (i.e., ICRS with IOL; ICRS with phakic IOL; ICRS with pseudophakic IOL; Corneal CXL and corneal refractive surgery; and CXL with phakic or pseudophakic IOL) and triple procedures with relative success (i.e., ICRS with CXL, PRK or phakic IOL) [394–396].

9.3.2. Corneal transplantation and implantation

Corneal transplantation is the traditional treatment for advanced keratoconus. Keratoconus has been reported to be the reason for 18% of penetrating keratoplasty procedures, and 40% of deep anterior lamellar keratoplasty interventions [397,398]. Anterior limiting lamina transplantation might be beneficial in certain cases of keratoconus with extreme corneal thinning, although further research is necessary to improve the technique [399,400]. Intrastromal implantation of stem cells has also been proposed for regeneration or subtotal replacement of the corneal stroma in advanced cases of keratoconus [401,402].

9.3.2.1. Keratoplasty. Penetrating keratoplasty (PK), which consists of the removal of the entire thickness of the cornea and replacement with donor tissue [403], is one of the most commonly used surgical techniques for advanced keratoconus that cannot be successfully managed with contact lenses [37,404–406], with 10 to 20% of keratoconics eventually undergoing PK [8,407,408].

Deep anterior lamellar keratoplasty (DALK) is another surgical technique used to replace diseased recipient stroma with donor corneal stroma, while the recipient corneal endothelium and posterior limiting lamina are retained. This technique preserves the ocular integrity, permitting earlier suture removal and faster visual rehabilitation due to faster wound recovery and, consequently, fewer wound healing-related

problems [409–411]. Patients that undergo PK are more likely to achieve better visual acuity than those that undergo DALK [405]; however, there is an increased risk of endothelial cell loss and graft rejection with PK compared to DALK [406].

9.3.2.2. Anterior limiting lamina transplantation. Anterior limiting lamina transplantation is a novel technique that may stabilise progressive ectatic corneal changes in eyes with advanced keratoconus, which are too steep or too thin for CXL or ICRS [399]. In this way, patients can maintain stable vision with contact lenses, and avoid or postpone more invasive corneal transplants, such as PK or DALK. Recently, a new technique has been reported in which an isolated anterior limiting lamina's layer is transplanted (as a corneal stromal inlay or as a corneal onlay) into a manually dissected mid-stromal corneal pocket in patients with advanced keratoconus. The technique has recently shown to be effective in halting keratoconus progression and maintaining visual acuity with contact lenses, at least up to 5–7 years postoperatively [400].

9.3.2.3. Intrastromal implantation of stem cells. Different approaches to regenerate or replace the corneal stroma in keratoconus have been tested *in-vitro* and *in-vivo* in preclinical studies and include a range of different stem cells such as: the intrastromal injection of stem cells alone; intrastromal implantation of stem cells with a biodegradable scaffold; intrastromal implantation of stem cells with a nonbiodegradable scaffold; and intrastromal implantation of stem cells with a decellularized corneal stromal scaffold [398,402].

10. Conclusions

Keratoconus is a bilateral and asymmetric ocular disease which has been traditionally described as a noninflammatory condition, but more recently it has been associated with ocular inflammation. It normally develops in the second and third decades of life and typically progresses until the fourth decade. The condition affects all ethnicities and both sexes. Epidemiological studies indicate substantial global variation in the prevalence and incidence of keratoconus, with highest rates typically occurring in 20- to 30-year-olds and Middle Eastern and Asian ethnicities. The adoption of new technologies for imaging the human cornea has contributed to a better understanding of the disease. These imaging techniques, together with the increased use of wavefront aberrometry, have allowed better characterisation of the optical, anatomical, biomechanical, and histopathological changes associated with keratoconus. Keratoconus progresses as a combination of simultaneously occurring destructive and healing processes. Corneal protrusion, the scissors reflex, corneal thinning, Fleischer's ring, and prominent corneal nerve fibres are the most prevalent clinical signs in keratoconus, with all these signs observed in over 50% of patients with keratoconus. However, the time course of the development of these clinical signs and their association with disease severity are highly variable. Although identifying clinical symptoms and slit-lamp findings in keratoconus are important, corneal topography is currently the primary diagnostic tool for keratoconus detection. In incipient cases, however, the use of a single parameter as a diagnostic factor is not sufficiently accurate, and pachymetry and corneal aberration data are now also commonly used in conjunction with corneal topography to aid early diagnosis and monitor progression and treatment outcomes. Corneal tomography that characterizes the anterior/posterior corneal surfaces, along with corneal thickness distribution, has been found to enhance the sensitivity and specificity for detecting corneal ectasia in comparison to corneal topography, thus increasing the ability to detect early or subclinical keratoconus. Furthermore, various machine learning algorithms can be developed using routinely collected clinical parameters that can assist in the objective detection of early forms of the disease. Keratoconus has long been considered to have a genetic

component. Although it is commonly an isolated ocular condition, it sometimes coexists with other ocular and systemic diseases. A family history of keratoconus, eye rubbing, eczema, asthma, and allergy are risk factors for developing keratoconus. Keratoconus severity and progression may be classified based on morphological features and disease evolution, ocular signs, and index-based systems. Treatment varies depending on disease severity and progression. Mild cases are typically treated with spectacles, moderate cases with contact lenses, while severe cases that cannot be managed with scleral contact lenses may require corneal surgery. Aberration-controlled soft contact lenses for keratoconus are being developed, particularly with regards to correcting vertical coma as this is typically the most elevated higher-order aberration in keratoconus. Corneoscleral and scleral lenses have gained significant popularity in recent years, particularly because these lenses have been able to provide successful outcomes when other contact lens options fail. There have also been significant developments in surgical options for keratoconus, with mild to moderate cases of progressive keratoconus now being commonly treated with corneal cross-linking; however, randomized studies with larger cohorts and longer follow-up periods are needed to determine which surgical procedure is most suitable for each patient. The substantial amount of research activity conducted over the last decade has contributed to advance our understanding of keratoconus.

References

- [1] Romero-Jiménez M, Santodomingo-Rubido J, Wolffsohn JS. Keratoconus: a review. *Cont Lens Anterior Eye* 2010;33:157–66. <https://doi.org/10.1016/j.clae.2010.04.006>.
- [2] Martínez-Abad A, Piñero DP. New perspectives on the detection and progression of keratoconus. *J Cataract Refract Surg* 2017;43:1213–27. <https://doi.org/10.1016/j.jcrs.2017.07.021>.
- [3] Loukovitis E, Kozeis N, Gatziofuz Z, Kozei A, Tsotridou E, Stoila M, et al. The proteins of keratoconus: a literature Review exploring their contribution to the pathophysiology of the disease. *Adv Ther* 2019;36:2205–22. <https://doi.org/10.1007/s12325-019-01026-0>.
- [4] Khalid ML, Helwa I, Drewry M, Seremwe M, Estes A, Liu Y. Molecular and histopathological changes associated with keratoconus. *Biomed Res Int* 2017;7803029. <https://doi.org/10.1155/2017/7803029>.
- [5] Grzybowski A, McGhee CNJ. The early history of keratoconus prior to Nottingham's landmark 1854 treatise on conical cornea: a review. *Clin Exp Optom* 2013;96:140–5. <https://doi.org/10.1111/cxo.12035>.
- [6] Li X, Rabinowitz YS, Rasheed K, Yang H. Longitudinal study of the normal eyes in unilateral keratoconus patients. *Ophthalmology* 2004;111:440–6. <https://doi.org/10.1016/j.ophtha.2003.06.020>.
- [7] Zadnik K, Barr JT, Gordon MO, Edrington TB. Biomicroscopic signs and disease severity in keratoconus. *Cornea* 1996;15:139–46. <https://doi.org/10.1097/00003226-199603000-00006>.
- [8] Kennedy RH, Bourne WM, Dyer JA. A 48-year clinical and epidemiologic study of keratoconus. *Am J Ophthalmol* 1986;101:267–73. [https://doi.org/10.1016/0002-9394\(86\)90817-2](https://doi.org/10.1016/0002-9394(86)90817-2).
- [9] Romero-Jiménez M, Santodomingo-Rubido J, González-Méjome JM. The thinnest, steepest, and maximum elevation corneal locations in noncontact and contact lens wearers in keratoconus. *Cornea* 2013;32:332–7. <https://doi.org/10.1097/ICO.0b013e318259c98a>.
- [10] Rabinowitz YS. Keratoconus. *Surv Ophthalmol* 1998;42:297–319. [https://doi.org/10.1016/S0039-6257\(97\)00119-7](https://doi.org/10.1016/S0039-6257(97)00119-7).
- [11] Krachmer JH, Feder RS, Belin MW. Keratoconus and related noninflammatory corneal thinning disorders. *Surv Ophthalmol* 1984;28:293–322. [https://doi.org/10.1016/0039-6257\(84\)90094-8](https://doi.org/10.1016/0039-6257(84)90094-8).
- [12] Wisse RPL, Kuiper JJW, Gans R, Imhof S, Radstake TRDJ, Van Der Lelij A. Cytokine expression in keratoconus and its corneal microenvironment: A systematic review. *Ocul Surf* 2015;13:272–83. <https://doi.org/10.1016/j.jtos.2015.04.006>.
- [13] Jun AS, Cope L, Speck C, Feng X, Lee S, Meng H, et al. Subnormal cytokine profile in the tear fluid of keratoconus patients. *PLoS ONE* 2011;6. <https://doi.org/10.1371/journal.pone.0016437>.
- [14] Lema I, Durán JA. Inflammatory molecules in the tears of patients with keratoconus. *Ophthalmology* 2005;112:654–9. <https://doi.org/10.1016/j.ophtha.2004.11.050>.
- [15] Lema I, Sobrino T, Durán JA, Brea D, Díez-Feijoo E. Subclinical keratoconus and inflammatory molecules from tears. *Br J Ophthalmol* 2009;93:820–4. <https://doi.org/10.1136/bjo.2008.144253>.
- [16] Balasubramanian SA, Mohan S, Pye DC, Willcox MDP. Proteases, proteolysis and inflammatory molecules in the tears of people with keratoconus. *Acta Ophthalmol* 2012;90:303–9. <https://doi.org/10.1111/j.1755-3768.2011.02369.x>.

- [17] Galvis V, Sherwin T, Tello A, Merayo J, Barrera R, Acera A. Keratoconus: an inflammatory disorder? *Eye* 2015;29:843–59. <https://doi.org/10.1038/eye.2015.63>.
- [18] McMonnies CW. Inflammation and keratoconus. *Optom Vis Sci* 2015;92:e35–41. <https://doi.org/10.1097/OPX.0000000000000455>.
- [19] Nichols JJ, Steger-May K, Edrington TB, Zadnik K. The relation between disease asymmetry and severity in keratoconus. *Br J Ophthalmol* 2004;88:788–91. <https://doi.org/10.1136/bjo.2003.034520>.
- [20] Burns DM, Johnston FM, Frazer DG, Patterson C, Jackson AJ. Keratoconus: an analysis of corneal asymmetry. *Br J Ophthalmol* 2004;88:1252–5. <https://doi.org/10.1136/bjo.2003.033670>.
- [21] Jones-Jordan LA, Walline JJ, Sinnott LT, Kymes SM, Zadnik K. Asymmetry in keratoconus and vision-related quality of life. *Cornea* 2013;32:267–72. <https://doi.org/10.1097/ICO.0b013e31825697c4>.
- [22] Chopra I, Jain AK. Between eye asymmetry in keratoconus in an Indian population. *Clin Exp Optom* 2005;88:146–52. <https://doi.org/10.1111/j.1444-0938.2005.tb06687.x>.
- [23] Zadnik K, Steger-May K, Fink BA, Joslin CE, Nichols JJ, Rosenstiel CE, et al. Between-eye asymmetry in keratoconus. *Cornea* 2002;21:671–9. <https://doi.org/10.1097/00003226-200210000-00008>.
- [24] Epidemiology is a science of high importance. *Nat Commun* 2018;9. doi: 10.1038/s41467-018-04243-3.
- [25] Spronk I, Korevaar JC, Poos R, Davids R, Hilderink H, Schellevis FG, et al. Calculating incidence rates and prevalence proportions: Not as simple as it seems. *BMC Public Health* 2019;19. <https://doi.org/10.1186/s12889-019-6820-3>.
- [26] Keiding N. Age-specific incidence and prevalence: a statistical perspective. *J R Stat Soc Ser A (Statistics Soc)* 1991;154:371. doi: 10.2307/2983150.
- [27] Flockezi E, Xanthopoulou K, Goebels S, Zemova E, Razafimino S, Hamon L, et al. Keratoconus staging by decades: a baseline ABCD classification of 1000 patients in the Homburg Keratoconus Center. *Br J Ophthalmol* 2020. <https://doi.org/10.1136/bjophthalmol-2020-316789>.
- [28] Hwang S, Lim DH, Chung TY. Prevalence and incidence of keratoconus in South Korea: a nationwide population-based study. *Am J Ophthalmol* 2018;192:56–64. <https://doi.org/10.1016/j.ajo.2018.04.027>.
- [29] Gordon-Shaag A, Millodot M, Shneur E, Liu Y. The genetic and environmental factors for keratoconus. *Biomed Res Int* 2015;2015. <https://doi.org/10.1155/2015/795738>.
- [30] Hofstetter HW. A keratoscopic survey of 13,395 eyes. *Optom Vis Sci* 1959;36: 3–11. <https://doi.org/10.1097/00006324-195901000-00002>.
- [31] Tanabe U, Fujiki K, Ogawa A, Ueda S, Kanai A. Prevalence of keratoconus patients in Japan. *J Japanese Ophthalmol Soc* 1985;89:407–11.
- [32] Ihalainen A. Clinical and epidemiological features of keratoconus genetic and external factors in the pathogenesis of the disease. *Acta Ophthalmol Suppl (Oxf)* 1986;178:1–64.
- [33] Santiago PY, Assouline M, Ducoussau F, Bazin S, Ballion JC, Mezraoui A, et al. P 143 Prevalence of keratoconus and corneal topography in young male subjects. *Vision Res* 1995;35:S178. [https://doi.org/10.1016/0042-6989\(95\)90459-x](https://doi.org/10.1016/0042-6989(95)90459-x).
- [34] Gorskova EN, Sevost'ianov EN. Epidemiology of keratoconus in the Urals. *Vestn Ophthalmol* 1998;114:38–40.
- [35] Pearson AR, Soneji B, Sarvananthan N, Sanford-Smith JH. Does ethnic origin influence the incidence or severity of keratoconus? *Eye* 2000;14:625–8. <https://doi.org/10.1038/eye.2000.154>.
- [36] Ota R, Fujiki K, Nakayasu K. Estimation of patient visit rate and incidence of keratoconus in the 23 wards of Tokyo. *Nihon Ganka Gakkai Zasshi* 2002;106: 365–72. [https://doi.org/10.1016/s0021-5155\(02\)00593-2](https://doi.org/10.1016/s0021-5155(02)00593-2).
- [37] Georgiou T, Funnell CL, Cassels-Brown A, O'Connor R. Influence of ethnic origin on the incidence of keratoconus and associated atopic disease in Asians and white patients. *Eye* 2004;18:379–83. <https://doi.org/10.1038/sj.eye.6700652>.
- [38] Assiri AA, Yousuf BI, Quantock AJ, Murphy PJ, Assiri AA. Incidence and severity of keratoconus in Asir province, Saudi Arabia. *Br J Ophthalmol* 2005;89:1403–6. <https://doi.org/10.1136/bjo.2005.074955>.
- [39] Jonas JB, Nangia V, Matin A, Kulkarni M, Bhojwani K. Prevalence and associations of keratoconus in rural Maharashtra in central India: the central India eye and medical study. *Am J Ophthalmol* 2009;148:760–5. <https://doi.org/10.1016/j.ajo.2009.06.024>.
- [40] Ljubic AD. Keratoconus and its prevalence in Macedonia. *Maced J Med Sci* 2009; 2:58–62. <https://doi.org/10.3889/MJMS.1857-5773.2009.0034>.
- [41] Reeves SW, Ellwein LB, Kim T, Constantine R, Lee PP. Keratoconus in the Medicare population. *Cornea* 2009;28:40–2. <https://doi.org/10.1097/ICO.0b013e3181839b06>.
- [42] Millodot M, Shneur E, Albou S, Atlani E, Gordon-Shaag A. Prevalence and associated factors of keratoconus in Jerusalem: a cross-sectional study. *Ophthalmic Epidemiol* 2011;18:91–7. <https://doi.org/10.3109/09286586.2011.560747>.
- [43] Waked N, Fayad AM, Fadlallah A, El Rami H. Dépistage du kératocône dans une population universitaire au Liban. *J Fr Ophtalmol* 2012;35:23–9. <https://doi.org/10.1016/j.jfo.2011.03.016>.
- [44] Xu L, Wang YX, Guo Y, You QS, Jonas JB. Prevalence and associations of steep cornea/keratoconus in greater Beijing. The Beijing eye study. *PLoS ONE* 2012;7. <https://doi.org/10.1371/journal.pone.0039313>.
- [45] Ziaei H, Jafarinasab MR, Javadi MA, Karimian F, Poorsalman H, Mahdavi M, et al. Epidemiology of keratoconus in an Iranian population. *Cornea* 2012;31: 1044–7. <https://doi.org/10.1097/ICO.0b013e31823f8d3c>.
- [46] Hashemi H, Beiranvand A, Khabazkhoob M, Asgari S, Emamian MH, Shariati M, et al. Prevalence of keratoconus in a population-based study in Shahroud. *Cornea* 2013;32:1441–5. <https://doi.org/10.1097/ICO.0b013e3182a0d014>.
- [47] Hashemi H, Khabazkhoob M, Fotouhi A. Topographic keratoconus is not rare in an Iranian population: the Tehran eye study. *Ophthalmic Epidemiol* 2013;20: 385–91. <https://doi.org/10.3109/09286586.2013.848458>.
- [48] Hashemi H, Khabazkhoob M, Yazdani N, Ostadimoghaddam H, Norouzrad R, Amanzadeh K, et al. The prevalence of keratoconus in a young population in Mashhad, Iran. *Ophthalmic Physiol Opt* 2014;34:519–27. <https://doi.org/10.1111/opo.12147>.
- [49] Barbara R, Gordon-Shaag A, Millodot M, Shneur E, Essa M, Anton M. Prevalence of Keratoconus among young Arab students in Israel. *Int J Keratoconus Ectatic Corneal Dis* 2014;3:9–14. <https://doi.org/10.5005/jp-journals-10025-1070>.
- [50] Valdez-García JE, Sepúlveda R, Salazar-Martínez JJ, Lozano-Ramírez JF. Prevalence of keratoconus in an adolescent population. *Rev Mex Oftalmol* 2014; 88:95–8. <https://doi.org/10.1016/j.mexoft.2014.03.002>.
- [51] Shehadeh MM, Diakonou VF, Jallil SA, Younis R, Qadoumi J, Al-Labadi L. Prevalence of keratoconus among a Palestinian tertiary student population. *Open Ophthalmol J* 2016;9:172–6. <https://doi.org/10.2174/1874364101509010172>.
- [52] Godefrooij DA, de Wit GA, Uiterwaal CS, Imhof SM, Wisse RPL. Age-specific incidence and prevalence of keratoconus: a nationwide registration study. *Am J Ophthalmol* 2017;175:169–72. <https://doi.org/10.1016/j.ajo.2016.12.015>.
- [53] Torres Netto EA, Al-Otaibi WM, Hafezi NL, Kling S, Al-Farhan HM, Randleman JB, et al. Prevalence of keratoconus in paediatric patients in Riyadh, Saudi Arabia. *Br J Ophthalmol* 2018;102:1436–41. <https://doi.org/10.1136/bjophthalmol-2017-311391>.
- [54] Bak-Nielsen S, Ramlau-Hansen CH, Ivarsen A, Plana-Ripoll O, Hjortdal J. Incidence and prevalence of keratoconus in Denmark – an update. *Acta Ophthalmol* 2019;97:752–5. <https://doi.org/10.1111/aos.14082>.
- [55] Papali-i-Curtin AT, Cox R, Ma T, Woods L, Covello A, Hall RC. Keratoconus prevalence among high school students in New Zealand. *Cornea* 2019;38:1382–9. <https://doi.org/10.1097/ICO.0000000000002054>.
- [56] Armstrong BK, Smith SD, Romac Coc I, Agarwal P, Mustapha N, Navon S. Screening for keratoconus in a high-risk adolescent population. *Ophthalmic Epidemiol* 2021;28:191–7. <https://doi.org/10.1080/09286586.2020.1804593>.
- [57] Özalp O, Atalay E, Yıldırım N. Prevalence and risk factors for keratoconus in a university-based population in Turkey. *J Cataract Refract Surg* 2021. <https://doi.org/10.1097/j.jcrs.0000000000000669>.
- [58] Mathew JH, Goosey JD, Bergmann JPG. Quantified histopathology of the keratoconic cornea. *Optom Vis Sci* 2011;88:988–97. <https://doi.org/10.1097/OPX.0b013e31821fbbd4>.
- [59] Hollingsworth JG, Efron N, Tullio AB. In vivo corneal confocal microscopy in keratoconus. *Ophthalmic Physiol Opt* 2005;25:254–60. <https://doi.org/10.1111/j.1475-1313.2005.00278.x>.
- [60] Sherwin T, Brookes NH. Morphological changes in keratoconus: pathology or pathogenesis. *Clin Exp Ophthalmol* 2004;32:211–7. <https://doi.org/10.1111/j.1442-9071.2004.00805.x>.
- [61] Naderan M, Jahanrad A, Balali S. Histopathologic findings of keratoconus corneas underwent penetrating keratoplasty according to topographic measurements and keratoconus severity. *Int J Ophthalmol* 2017;10:1640–6. <https://doi.org/10.18240/ijo.2017.11.02>.
- [62] Sykakis E, Carley F, Irion L, Denton J, Hillarby MC. An in depth analysis of histopathological characteristics found in keratoconus. *Pathology* 2012;44: 234–9. <https://doi.org/10.1097/PAT.0b013e31828351b42>.
- [63] Fernandes BF, Logan P, Zajdenweber ME, Santos LN, Cheema DP, Burnier MN. Histopathological study of 49 cases of keratoconus. *Pathology* 2008;40:623–6. <https://doi.org/10.1080/00313020802320648>.
- [64] Erie JC, Patel SV, McLaren JW, Nau CB, Hodge DO, Bourne WM. Keratocyte density in keratoconus. A confocal microscopy study. *Am J Ophthalmol* 2002; 134:689–95. [https://doi.org/10.1016/S0002-9394\(02\)01698-7](https://doi.org/10.1016/S0002-9394(02)01698-7).
- [65] Uçakhan ÖÖ, Kanpolat A, Yılmaz N, Özkan M. In vivo confocal microscopy findings in keratoconus. *Eye Contact Lens* 2006;32:183–91. <https://doi.org/10.1097/01.icl.0000189038.74139.4a>.
- [66] Bitirgen G, Ozkagnici A, Bozkurt B, Malik RA. In vivo corneal confocal microscopic analysis in patients with keratoconus. *Int J Ophthalmol* 2015;8: 534–9. <https://doi.org/10.3980/j.issn.2222-3959.2015.03.17>.
- [67] Hollingsworth JG, Bonshek RE, Efron N. Correlation of the appearance of the keratoconic cornea in vivo by confocal microscopy and in vitro by light microscopy. *Cornea* 2005;24:397–405. <https://doi.org/10.1097/01.icl.0000151548.46231.27>.
- [68] Mocan MC, Yilmaz PT, Irkeç M, Orhan M. In vivo confocal microscopy for the evaluation of corneal microstructure in keratoconus. *Curr Eye Res* 2008;33: 933–9. <https://doi.org/10.1080/02713680802439219>.
- [69] Scroggs MW, Proia AD. Histopathological variation in keratoconus. *Cornea* 1992; 11:553–9. <https://doi.org/10.1097/00003226-199211000-00012>.
- [70] Weed KH, MacEwen CJ, Cox A, McGhee CNJ. Quantitative analysis of corneal microstructure in keratoconus utilising in vivo confocal microscopy. *Eye* 2007;21: 614–23. <https://doi.org/10.1038/sj.eye.6702286>.
- [71] Niederer RL, Perumal D, Sherwin T, McGhee CNJ. Laser scanning in vivo confocal microscopy reveals reduced innervation and reduction in cell density in all layers of the keratoconic cornea. *Invest Ophthalmol Vis Sci* 2008;49:2964–70. <https://doi.org/10.1167/iov.07-0968>.
- [72] Sawaguchi S, Fukuchi T, Abe H, Kaiya T, Sugar J, Yue BVJT. Three-dimensional scanning electron microscopic study of keratoconus corneas. *Arch Ophthalmol* 1998;116:62–8. <https://doi.org/10.1001/archoph.116.1.62>.
- [73] Patel DV, McGhee CNJ. Mapping the corneal sub-basal nerve plexus in keratoconus by in vivo laser scanning confocal microscopy. *Invest Ophthalmol Vis Sci* 2006;47:1348–51. <https://doi.org/10.1167/iov.05-1217>.

- [74] Mannion LS, Tromans C, O'Donnell C. An evaluation of corneal nerve morphology and function in moderate keratoconus. *Cont Lens Anterior Eye* 2005; 28:185–92. <https://doi.org/10.1016/j.clae.2005.10.005>.
- [75] Patel DV, Ku JYF, Johnson R, McGhee CNJ. Laser scanning in vivo confocal microscopy and quantitative aesthesiometry reveal decreased corneal innervation and sensation in keratoconus. *Eye* 2009;23:586–92. <https://doi.org/10.1038/eye.2008.52>.
- [76] Brookes NH, Loh IP, Clover GM, Poole CA, Sherwin T. Involvement of corneal nerves in the progression of keratoconus. *Exp Eye Res* 2003;77:515–24. [https://doi.org/10.1016/S0014-4835\(03\)00148-9](https://doi.org/10.1016/S0014-4835(03)00148-9).
- [77] Sherwin T, Brookes NH, Loh IP, Poole CA, Clover GM. Cellular incursion into Bowman's membrane in the peripheral cone of the keratoconic cornea. *Exp Eye Res* 2002;74:473–82. <https://doi.org/10.1006/exer.2001.1157>.
- [78] Morishige N, Wahlert AJ, Kenney MC, Brown DJ, Kawamoto K, Chikama TI, et al. Second-harmonic imaging microscopy of normal human and keratoconus cornea. *Invest Ophthalmol Vis Sci* 2007;48:1087–94. <https://doi.org/10.1167/iovs.06-1177>.
- [79] Morishige N, Shin-Gyou-Uchi R, Azumi H, Ohta H, Morita Y, Yamada N, et al. Quantitative analysis of collagen lamellae in the normal and keratoconic human cornea by second harmonic generation imaging microscopy. *Invest Ophthalmol Vis Sci* 2014;55:8377–85. <https://doi.org/10.1167/iovs.14-15348>.
- [80] Meek KM, Tuft SJ, Huang Y, Gill PS, Hayes S, Newton RH, et al. Changes in collagen orientation and distribution in keratoconus corneas. *Invest Ophthalmol Vis Sci* 2005;46:1948–56. <https://doi.org/10.1167/iovs.04-1253>.
- [81] Akhtar S, Bron AJ, Salvi SM, Hawksworth NR, Tuft SJ, Meek KM. Ultrastructural analysis of collagen fibrils and proteoglycans in keratoconus. *Acta Ophthalmol* 2008;86:764–72. <https://doi.org/10.1111/j.1755-3768.2007.01142.x>.
- [82] Mathew JH, Goosey JD, Söderberg PG, Bergmanson JPG. Lamellar changes in the keratoconic cornea. *Acta Ophthalmol* 2015;93:767–73. <https://doi.org/10.1111/aos.12811>.
- [83] Hollingsworth JG, Efron N. Observations of banding patterns (Vogt striae) in keratoconus: a confocal microscopy study. *Cornea* 2005;24. <https://doi.org/10.1097/ICO.0000141231.03225.d8>.
- [84] Fan Gaskin JC, Patel DV, McGhee CNJ. Acute corneal hydrops in keratoconus – new perspectives. *Am J Ophthalmol* 2014;157:921–8. <https://doi.org/10.1016/j.ajo.2014.01.017>.
- [85] Thota S, Miller WL, Bergmanson JPG. Acute corneal hydrops: a case report including confocal and histopathological considerations. *Cont Lens Anterior Eye* 2006;29:69–73. <https://doi.org/10.1016/j.clae.2005.12.001>.
- [86] Rajaraman R, Singh S, Raghavan A, Karkhanis A. Efficacy and safety of intracameral perfluoropropane (C3F₈) tamponade and compression sutures for the management of acute corneal hydrops. *Cornea* 2009;28:317–20. <https://doi.org/10.1097/ICO.0b013e31818ada0b>.
- [87] Yahia Chérif H, Gueudry J, Afriat M, Delcampe A, Attal P, Gross H, et al. Efficacy and safety of pre-Descemet's membrane sutures for the management of acute corneal hydrops in keratoconus. *Br J Ophthalmol* 2015;99:773–7. <https://doi.org/10.1136/bjophthalmol-2014-306287>.
- [88] Efron N, Hollingsworth JG. New perspectives on keratoconus as revealed by corneal confocal microscopy. *Clin Exp Optom* 2008;91:34–55. <https://doi.org/10.1111/j.1444-0938.2007.00195.x>.
- [89] Sandali O, El Sanharawi M, Temstet C, Hamiche T, Galan A, Ghouali W, et al. Fourier-domain optical coherence tomography imaging in keratoconus: a corneal structural classification. *Ophthalmology* 2013;120:2403–12. <https://doi.org/10.1016/j.ophtha.2013.05.027>.
- [90] El-Agha MSH, El Sayed YM, Harhara RM, Essam HM. Correlation of corneal endothelial changes with different stages of keratoconus. *Cornea* 2014;33:707–11. <https://doi.org/10.1097/ICO.0000000000000134>.
- [91] Mathan JJ, Gokul A, Simkin SK, Meyer JJ, Patel DV, McGhee CNJ. Topographic screening reveals keratoconus to be extremely common in Down syndrome. *Clin Exp Ophthalmol* 2020;48:1160–7. <https://doi.org/10.1111/ceo.13852>.
- [92] Elder MJ. Leber congenital amaurosis and its association with keratoconus and keratoglobus. *J Pediatr Ophthalmol Strabismus* 1994;31:38–40. <https://doi.org/10.3928/0191-3913-19940101-08>.
- [93] Damji KF, Sohocki MM, Khan R, Gupta SK, Rahim M, Loyer M, et al. Leber's congenital amaurosis with anterior keratoconus in Pakistani families is caused by the Trp278X mutation in the AIPL1 gene on 17p. *Can J Ophthalmol* 2001;36:252–9. [https://doi.org/10.1016/S0008-4182\(01\)80018-1](https://doi.org/10.1016/S0008-4182(01)80018-1).
- [94] Robertson I. Keratoconus and the Ehlers Danlos syndrome: a new aspect of keratoconus. *Med J Aust* 1975;1:571–3. <https://doi.org/10.5694/j.1326-5377.1975.tb111590.x>.
- [95] Lee A, Sakhalkar MV. Ocular manifestations of Noonan syndrome in twin siblings: a case report of keratoconus with acute corneal hydrops. *Indian J Ophthalmol* 2014;62:1171–3. <https://doi.org/10.4103/0301-4738.126992>.
- [96] Rabinowitz YS, Galvis V, Tello A, Rueda D, García JD. Genetics vs chronic corneal mechanical trauma in the etiology of keratoconus. *Exp Eye Res* 2021;202:108328. <https://doi.org/10.1016/j.exer.2020.108328>.
- [97] Gordon-Shaag A, Millodot M, Essa M, Garth J, Ghara M, Shneur E. Is consanguinity a risk factor for keratoconus? *Optom Vis Sci* 2013;90:448–54. <https://doi.org/10.1097/OPX.0b013e31828da95c>.
- [98] Almusawi LA, Hamied FM. Risk factors for development of keratoconus: a matched pair case-control study. *Clin Ophthalmol* 2021;15:3473–9. <https://doi.org/10.2147/OPHT.S248724>.
- [99] Lapeyre G, Fournie P, Vernet R, Roseng S, Maleceze F, Bouzigon E, et al. Keratoconus prevalence in families: a French study. *Cornea* 2020;39:1473–9. <https://doi.org/10.1097/ICO.0000000000002546>.
- [100] Edwards M, McGhee CNJ, Dean S. The genetics of keratoconus. *Clin Exp Ophthalmol* 2001;29:345–51. <https://doi.org/10.1046/j.1442-9071.2001.d01-16.x>.
- [101] Tuft SJ, Hassan H, George S, Frazer DG, Willoughby CE, Liskova P. Keratoconus in 18 pairs of twins. *Acta Ophthalmol* 2012;90:e482–6. <https://doi.org/10.1111/j.1755-3768.2012.02448.x>.
- [102] Wang Y, Rabinowitz YS, Rotter JI, Yang H. Genetic epidemiological study of keratoconus: Evidence for major gene determination. *Am J Med Genet* 2000;93:403–9. [https://doi.org/10.1002/1096-8628\(20000828\)93:5<403::AID-AJMG11>3.0.CO;2-A](https://doi.org/10.1002/1096-8628(20000828)93:5<403::AID-AJMG11>3.0.CO;2-A).
- [103] Bisceglia L, De Bonis P, Pizzicoli C, Fischetti L, Laborante A, Di Perna M, et al. Linkage analysis in keratoconus: Replication of locus 5q21.2 and identification of other suggestive loci. *Investig Ophthalmol Vis Sci* 2009;50:1081–6. <https://doi.org/10.1167/iovs.08-2382>.
- [104] Gonzalez V, McDonnell PJ. Computer-assisted corneal topography in parents of patients with keratoconus. *Arch Ophthalmol* 1992;110:1412–4. <https://doi.org/10.1001/archophth.1992.01080220074024>.
- [105] Kriszt Á, Losonczy G, Berta A, Vereb G, Takács L. Segregation analysis suggests that keratoconus is a complex non-mendelian disease. *Acta Ophthalmol* 2014;92:e562–8. <https://doi.org/10.1111/aos.12389>.
- [106] Chen S, Li XY, Jin JJ, Shen RJ, Mao JY, Cheng FF, et al. Genetic Screening Revealed Latent Keratoconus in Asymptomatic Individuals. *Front Cell. Dev Biol* 2021;9:650344. <https://doi.org/10.3389/fcell.2021.650344>.
- [107] Shneur E, Frucht-Pery J, Granit E, Gordon-Shaag A. The prevalence of corneal abnormalities in first-degree relatives of patients with keratoconus: a prospective case-control study. *Ophthalmic Physiol Opt* 2020;40:442–51. <https://doi.org/10.1111/opo.12706>.
- [108] Bykhovskaya Y, Rabinowitz YS. Update on the genetics of keratoconus. *Exp Eye Res* 2021;202:108398. <https://doi.org/10.1016/j.exer.2020.108398>.
- [109] Bykhovskaya Y, Li X, Taylor KD, Haritunians T, Rotter JI, Rabinowitz YS. Linkage analysis of high-density SNPs confirms keratoconus locus at 5q chromosomal region. *Ophthalmic Genet* 2016;37:109–10. <https://doi.org/10.3109/13816810.2014.889172>.
- [110] Mas Tur V, MacGregor C, Jayaswal R, O'Brart D, Maycock N. A review of keratoconus: diagnosis, pathophysiology, and genetics. *Surv Ophthalmol* 2017; 62:770–83. <https://doi.org/10.1016/j.survophthal.2017.06.009>.
- [111] Kenney MC, Brown DJ. The cascade hypothesis of keratoconus. *Contact Lens Anterior Eye* 2003;26. [https://doi.org/10.1016/S1367-0484\(03\)00022-5](https://doi.org/10.1016/S1367-0484(03)00022-5).
- [112] Yam GHF, Fuest M, Zhou L, Liu YC, Deng L, Chan ASY, et al. Differential epithelial and stromal protein profiles in cone and non-cone regions of keratoconus corneas. *Sci Rep* 2019;9:2965. <https://doi.org/10.1038/s41598-019-39182-6>.
- [113] Srivastava OP, Chandrasekaran D, Pfister RR. Molecular changes in selected epithelial proteins in human keratoconus corneas compared to normal corneas. *Mol Vis* 2006;12:1615–25.
- [114] Navel V, Maleceze F, Pereira B, Baker JS, Maleceze F, Sapin V, et al. Oxidative and antioxidative stress markers in keratoconus: a systematic review and meta-analysis. *Acta Ophthalmol* 2020;99:e777–94. <https://doi.org/10.1111/aos.14714>.
- [115] Zhou L, Sawaguchi S, Twining SS, Sugar J, Feder RS, Yue BYJT. Expression of degradative enzymes and protease inhibitors in corneas with keratoconus. *Invest Ophthalmol Vis Sci* 1998;39:1117–24.
- [116] Balasubramanian SA, Pye DC, Willcox MDP. Are proteinases the reason for keratoconus. *Curr Eye Res* 2010;35:185–91. <https://doi.org/10.3109/02713680903477824>.
- [117] di Martino E, Ali M, Inglehearn CF. Matrix metalloproteinases in keratoconus – too much of a good thing? *Exp Eye Res* 2019;182. doi: 10.1016/j.exer.2019.03.016.
- [118] Alkanaana A, Barsotti R, Kirat O, Khan A, Almubrad T, Akhtar S. Collagen fibrils and proteoglycans of peripheral and central stroma of the keratoconus cornea – ultrastructure and 3D transmission electron tomography. *Sci Rep* 2019;9:19963. <https://doi.org/10.1038/s41598-019-56529-1>.
- [119] Göttinger E, Pircher M, Dejaco-Ruhswurm I, Kaminski S, Skorpik C, Hitzingerberger CK. Imaging of birefringent properties of keratoconus corneas by polarization-sensitive optical coherence tomography. *Investig Ophthalmol Vis Sci* 2007;48:3551–8. <https://doi.org/10.1167/iovs.06-0727>.
- [120] Abdul-Maksoud RS, Fouad RA, Elsayed TG, Ibrahim RA, Badawi AE. The impact of catalase and glutathione peroxidase-1 genetic polymorphisms on their enzyme activities among Egyptian patients with keratoconus. *J Gene Med* 2020;22:e3192. <https://doi.org/10.1002/jgm.3192>.
- [121] Gondhowiardjo TD, Van Haeringen NJ. Corneal aldehyde dehydrogenase, glutathione reductase, and glutathione s-transferase in pathologic corneas. *Cornea* 1993;12:310–4. <https://doi.org/10.1097/00003226-199307000-00006>.
- [122] Behndig A, Svensson B, Marklund SL, Karlsson K. Superoxide dismutase isoenzymes in the human eye. *Invest Ophthalmol Vis Sci* 1998;39:471–5.
- [123] Göncü T, Akal A, Adibelli FM, Çakmak S, Sezen H, Yilmaz ÖF. Tear film and serum prolidase activity and oxidative stress in patients with keratoconus. *Cornea* 2015;34:1019–23. <https://doi.org/10.1097/ICO.0000000000000510>.
- [124] Kiliç R, Cumurcu T, Sancaktar E, Evliyaolu O, Sezer H. Systemic prolidase activity and oxidative stress in keratoconus. *Curr Eye Res* 2016;41:28–33. <https://doi.org/10.3109/02713683.2015.1004717>.
- [125] Shetty R, Sharma A, Pahuja N, Chevour P, Padmajan N, Dhamodaran K, et al. Oxidative stress induces dysregulated autophagy in corneal epithelium of keratoconus patients. *PLoS ONE* 2017;12:e0184628. <https://doi.org/10.1371/journal.pone.0184628>.

- [126] Amit C, Padmanabhan P, Elchuri SV, Narayanan J. Probing the effect of matrix stiffness in endocytic signalling pathway of corneal epithelium. *Biochem Biophys Res Commun* 2020;525:280–5. <https://doi.org/10.1016/j.bbrc.2020.02.067>.
- [127] Gasset AR, Houde WL, Garcia-Bengochea M. Hard contact lens wear as an environmental risk in keratoconus. *Am J Ophthalmol* 1978;85:339–41. [https://doi.org/10.1016/S0002-9394\(14\)77725-6](https://doi.org/10.1016/S0002-9394(14)77725-6).
- [128] Ghosh S, Mutalib HA, Kaur S, Ghoshal R, Retnasabapathy S. Effects of contact lens wearing on keratoconus: a confocal microscopy observation. *Int J Ophthalmol* 2017;10:228–34. <https://doi.org/10.18240/ijo.2017.02.08>.
- [129] Ahuja P, Dadachanji Z, Shetty R, Nagarajan SA, Khamar P, Sethu S, et al. Relevance of IgE, allergy and eye rubbing in the pathogenesis and management of Keratoconus. *Indian J Ophthalmol* 2020;68:2067–74. https://doi.org/10.4103/ijo.IJO_1191_19.
- [130] Hashemi H, Heydarian S, Hooshmand E, Saatchi M, Yekta A, Aghamirsalim M, et al. The prevalence and risk factors for keratoconus: a systematic review and meta-analysis. *Cornea* 2020;39:263–70. <https://doi.org/10.1097/ICO.0000000000002150>.
- [131] Kemp EG, Lewis CJ. Immunoglobulin patterns in keratoconus with particular reference to total and specific IgE levels. *Br J Ophthalmol* 1982;66:717–20. <https://doi.org/10.1136/bjo.66.11.717>.
- [132] Claessens JLL, Godefrooij DA, Vink G, Frank LE, Wisse RPL. Nationwide epidemiological approach to identify associations between keratoconus and immune-mediated diseases. *Br J Ophthalmol* 2021. <https://doi.org/10.1136/bjophthalmol-2021-318804>.
- [133] Gomes JAP, Tan D, Rapuano CJ, Belin MW, Ambrósio R, Guell JL, et al. Global consensus on keratoconus and ectatic diseases. *Cornea* 2015;34:359–69. <https://doi.org/10.1097/ICO.0000000000000408>.
- [134] Henriquez MA, Hadid M, Izquierdo L. A systematic review of subclinical keratoconus and forme fruste keratoconus. *J Refract Surg* 2020;36:270–9. <https://doi.org/10.3928/1081597X-20200212-03>.
- [135] Toprak I, Vega A, Alió Del Barrio JL, Espla E, Cavas F, Alió JL. Diagnostic value of corneal epithelial and stromal thickness distribution profiles in forme fruste keratoconus and subclinical keratoconus. *Cornea* 2021;40:61–72. <https://doi.org/10.1097/ICO.0000000000002435>.
- [136] Toprak I, Cavas F, Velázquez JS, Alió del Barrio JL, Alió JL. Subclinical keratoconus detection with three-dimensional (3-D) morphogeometric and volumetric analysis. *Acta Ophthalmol* 2020;98:e933–42. <https://doi.org/10.1111/aos.14433>.
- [137] Prisant O, Legeais JM, Renard G. Superior keratoconus. *Cornea* 1997;16:693–4. <https://doi.org/10.1097/00003226-199711000-00016>.
- [138] Tananuvat N, Leeungurasatien P, Wiriyaluppa C. Superior keratoconus with hydrops. *Int Ophthalmol* 2009;29:419–21. <https://doi.org/10.1007/s10792-008-9244-0>.
- [139] Weed KH, McGhee CNJ, MacEwen CJ. Atypical unilateral superior keratoconus in young males. *Contact Lens Anterior Eye* 2005;28:177–9. <https://doi.org/10.1016/j.clae.2005.10.002>.
- [140] Rafati S, Hashemi H, Nabovati P, Doostdar A, Yekta A, Aghamirsalim M, et al. Demographic profile, clinical, and topographic characteristics of keratoconus patients attending at a tertiary eye center. *J Curr Ophthalmol* 2019;31:268–74. <https://doi.org/10.1016/j.joco.2019.01.013>.
- [141] Naderan M, Jahanrad A, Farjadnia M. Clinical biomicroscopy and retinoscopy findings of keratoconus in a Middle Eastern population. *Clin Exp Optom* 2018;101:46–51. <https://doi.org/10.1111/cxo.12579>.
- [142] Fleischer B. Über Keratoconus und eigenartige Pigmentbildung in der kornea. *München Med Wschr* 1906;53:625–6.
- [143] Edrington TB, Zadnik K, Barr JT. Keratoconus. *Optom Clin* 1995;4:65–73. https://doi.org/10.1007/978-3-642-35951-4_439-4.
- [144] Zadnik K, Barr JT, Edrington TB, Everett DF, Jameson M, McMahon TT, et al. Baseline findings in the collaborative longitudinal evaluation of keratoconus (CLEK) study. *Invest Ophthalmol Vis Sci* 1998;39:2537–46.
- [145] Kriszt Á, Losonczy G, Berta A, Takács L. Presence of Fleischer ring and prominent corneal nerves in keratoconus relatives and normal controls. *Int J Ophthalmol* 2015;8:922–7. <https://doi.org/10.3980/j.issn.2222-3959.2015.05.12>.
- [146] Barr JT, Wilson BS, Gordon MO, Rah MJ, Riley C, Kollbaum PS, et al. Estimation of the incidence and factors predictive of corneal scarring in the Collaborative Longitudinal Evaluation of Keratoconus (CLEK) study. *Cornea* 2006;25:16–25. <https://doi.org/10.1097/01.icc.0000164831.87593.08>.
- [147] Gold J, Chauhan V, Rojanasthien S, Fitzgerald J. Munson's sign: An obvious finding to explain acute vision loss. *Clin Pract Cases Emerg Med* 2019;3:312–3. <https://doi.org/10.5811/cpcem.2019.5.42793>.
- [148] Rizzuti AB. Diagnostic illumination test for keratoconus. *Am J Ophthalmol* 1970;70:141–3. [https://doi.org/10.1016/0002-9394\(70\)90681-1](https://doi.org/10.1016/0002-9394(70)90681-1).
- [149] Kumar M, Shetty R, Lalgudi VG, Khamar P, Vincent SJ. Scleral lens visual rehabilitation of sequential bilateral corneal hydrops with post-lasik ectasia. *Eye Contact Lens* 2020;Online ahe. doi: 10.1097/icl.0000000000000766.
- [150] Kreps EO, Claerhout I, Koppen C. The outcome of scleral lens fitting for keratoconus with resolved corneal hydrops. *Cornea* 2019;38:855–8. <https://doi.org/10.1097/ICO.0000000000001946>.
- [151] Barsam A, Brennan N, Petruskin H, Xing W, Quartilho A, Bunce C, et al. Case-control study of risk factors for acute corneal hydrops in keratoconus. *Br J Ophthalmol* 2017;101:499–502. <https://doi.org/10.1136/bjophthalmol-2015-308251>.
- [152] Zhang X, Munir SZ, Sami Karim SA, Munir WM. A review of imaging modalities for detecting early keratoconus. *Eye* 2021;35:173–87. <https://doi.org/10.1038/s41433-020-1039-1>.
- [153] Kanclerz P, Khoramnia R, Wang X. Current developments in corneal topography and tomography. *Diagnostics* 2021;11:1466. <https://doi.org/10.3390/diagnostics11081466>.
- [154] Ambrósio R, Belin MW. Imaging of the cornea: topography vs tomography. *J Refract Surg* 2010;26:847–9. <https://doi.org/10.3928/1081597X-20101006-01>.
- [155] Cao K, Verspoor K, Sahebajda S, Baird PN. Evaluating the performance of various machine learning algorithms to detect subclinical keratoconus. *Transl Vis Sci Technol* 2020;9:1–11. <https://doi.org/10.1167/TVST.9.2.24>.
- [156] Keeler R, Singh AD, Dua HS. Carving the cornea: The von Hippel Trephine. *Br J Ophthalmol* 2009;93:847. <https://doi.org/10.1136/bjo.2008.147371>.
- [157] Reinstein DZ, Archer TJ, Gobbe M. Corneal epithelial thickness profile in the diagnosis of keratoconus. *J Refract Surg* 2009;25:604–10. <https://doi.org/10.3928/1081597X-20090610-06>.
- [158] Reinstein DZ, Gobbe M, Archer TJ, Silverman RH, Coleman J. Epithelial, stromal, and total corneal thickness in keratoconus: Three-dimensional display with Artemis very-high frequency digital ultrasound. *J Refract Surg* 2010;26:259–71. <https://doi.org/10.3928/1081597X-20100218-01>.
- [159] Franco J, White CA, Kruhl JN. Analysis of compensatory corneal epithelial thickness changes in keratoconus using corneal tomography. *Cornea* 2020;39:298–302. <https://doi.org/10.1097/ICO.0000000000002156>.
- [160] Xu Z, Jiang J, Yang C, Huang S, Peng M, Li W, et al. Value of corneal epithelial and Bowman's layer vertical thickness profiles generated by UHR-OCT for sub-clinical keratoconus diagnosis. *Sci Rep* 2016;6. <https://doi.org/10.1038/srep31550>.
- [161] Zhou W, Stojanovic A. Comparison of corneal epithelial and stromal thickness distributions between eyes with keratoconus and healthy eyes with corneal astigmatism ≥ 2.0 D. *PLoS One* 2014;9:e85994. <https://doi.org/10.1371/journal.pone.0085994>.
- [162] Li Y, Chamberlain W, Tan O, Brass R, Weiss JL, Huang D. Subclinical keratoconus detection by pattern analysis of corneal and epithelial thickness maps with optical coherence tomography. *J Cataract Refract Surg* 2016;42:284–95. <https://doi.org/10.1016/j.jcrs.2015.09.021>.
- [163] Li Y, Tan O, Brass R, Weiss JL, Huang D. Corneal epithelial thickness mapping by fourier-domain optical coherence tomography in normal and keratoconic eyes. *Ophthalmology* 2012;119:2425–33. <https://doi.org/10.1016/j.ophtha.2012.06.023>.
- [164] Vega-Estrada A, Mimouni M, Espla E, Alió del Barrio J, Alió JL. Corneal epithelial thickness intrasubject repeatability and its relation with visual limitation in keratoconus. *Am J Ophthalmol* 2019;200:255–62. <https://doi.org/10.1016/j.ajo.2019.01.015>.
- [165] Yang Y, Pavlatos E, Chamberlain W, Huang D, Li Y. Keratoconus detection using OCT corneal and epithelial thickness map parameters and patterns. *J Cataract Refract Surg* 2021;47:759–66. <https://doi.org/10.1097/j.jcrs.0000000000000498>.
- [166] Saad A, Gatinel D. Topographic and tomographic properties of forme fruste keratoconus corneas. *Investig Ophthalmol Vis Sci* 2010;51:5546–55. <https://doi.org/10.1167/iov.10-5369>.
- [167] Rao SN, Raviv T, Majmudar PA, Epstein RJ. Role of Orbscan II in screening keratoconus suspects before refractive corneal surgery. *Ophthalmology* 2002;109:1642–6. [https://doi.org/10.1016/S0161-6420\(02\)01121-1](https://doi.org/10.1016/S0161-6420(02)01121-1).
- [168] Schlegel Z, Hoang-Xuan T, Gatinel D. Comparison of and correlation between anterior and posterior corneal elevation maps in normal eyes and keratoconus-suspect eyes. *J Cataract Refract Surg* 2008;34:789–95. <https://doi.org/10.1016/j.jcrs.2007.12.036>.
- [169] Belin MW, Khachikian SS. An introduction to understanding elevation-based topography: How elevation data are displayed - A review. *Clin Exp Ophthalmol* 2009;37:14–29. <https://doi.org/10.1111/j.1442-9071.2008.01821.x>.
- [170] De Sanctis U, Arago V, Dalmaso P, Brusasco L, Grignolo F. Diagnosis of subclinical keratoconus using posterior elevation measured with 2 different methods. *Cornea* 2013;32:911–5. <https://doi.org/10.1097/ICO.0b013e3182854774>.
- [171] Muftuoglu O, Ayar O, Ozulken K, Ozyol E, Akinci A. Posterior corneal elevation and back difference corneal elevation in diagnosing forme fruste keratoconus in the fellow eyes of unilateral keratoconus patients. *J Cataract Refract Surg* 2013;39:1348–57. <https://doi.org/10.1016/j.jcrs.2013.03.023>.
- [172] Smadja D, Santhiago MR, Mello GR, Krueger RR, Colin J, Touboul D. Influence of the reference surface shape for discriminating between normal corneas, subclinical keratoconus, and keratoconus. *J Refract Surg* 2013;29:274–81. <https://doi.org/10.3928/1081597X-20130318-07>.
- [173] Sideroudi H, Labiris G, Giarmoukakis A, Bougatou N, Kozobolis V. Contribution of reference bodies in diagnosis of keratoconus. *Optom Vis Sci* 2014;91:676–81. <https://doi.org/10.1097/OPX.0000000000000258>.
- [174] Golan O, Hwang ES, Lang P, Santhiago MR, Abulafia A, Touboul D, et al. Differences in posterior corneal features between normal corneas and subclinical keratoconus. *J Refract Surg* 2018;34:664–70. <https://doi.org/10.3928/1081597X-20180823-02>.
- [175] Cavas-Martínez F, Fernández-Pacheco DG, De La Cruz-Sánchez E, Nieto Martínez J, Fernández Cañavate FJ, Vega-Estrada A, et al. Geometrical custom modeling of human cornea in vivo and its use for the diagnosis of corneal ectasia. *PLoS ONE* 2014;9:e110249. <https://doi.org/10.1371/journal.pone.0110249>.
- [176] Cavas-Martínez F, Bataille L, Fernández-Pacheco DG, Cañavate FJ, Alió JL. A new approach to keratoconus detection based on corneal morphogeometric analysis. *PLoS ONE* 2017;12:e0184569. <https://doi.org/10.1371/journal.pone.0184569>.

- [177] Kitazawa K, Itoi M, Yokota I, Wakimasu K, Cho Y, Nakamura Y, et al. Involvement of anterior and posterior corneal surface area imbalance in the pathological change of keratoconus. *Sci Rep* 2018;8:14993. <https://doi.org/10.1038/s41598-018-33490-z>.
- [178] Itoi M, Kitazawa K, Yokota I, Wakimasu K, Cho Y, Nakamura Y, et al. Anterior and posterior ratio of corneal surface areas: A novel index for detecting early stage keratoconus. *PLoS ONE* 2020;15:e0231074. <https://doi.org/10.1371/journal.pone.0231074>.
- [179] Consejo A, Alonso-Caneiro D, Wojtkowski M, Vincent SJ. Corneal tissue properties following scleral lens wear using Scheimpflug imaging. *Ophthalmic Physiol Opt* 2020;40:595–606. <https://doi.org/10.1111/opo.12710>.
- [180] Consejo A, Gławdecka K, Karnowski K, Solarski J, Rozema JJ, Wojtkowski M, et al. Corneal properties of keratoconus based on Scheimpflug light intensity distribution. *Invest Ophthalmol Vis Sci* 2019;60:3197–203. <https://doi.org/10.1167/iovs.19-26963>.
- [181] Consejo A, Solarski J, Karnowski K, Rozema JJ, Wojtkowski M, Iskander DR. Keratoconus detection based on a single Scheimpflug image. *Transl Vis Sci Technol* 2020;9:1–12. <https://doi.org/10.1167/tvst.9.7.36>.
- [182] Jiménez-García M, Ni Dhubhghaill S, Consejo A, Hershko S, Koppen C, Rozema JJ. Scheimpflug densitometry in keratoconus: A new method of visualizing the cone. *Cornea* 2021;40:194–202. <https://doi.org/10.1097/ICO.0000000000002458>.
- [183] Ting DSJ, Foo VHX, Yang LWY, Sia JT, Ang M, Lin H, et al. Artificial intelligence for anterior segment diseases: Emerging applications in ophthalmology. *Br J Ophthalmol* 2021;105:158–68. <https://doi.org/10.1136/bjophthalmol-2019-315651>.
- [184] Lin SR, Ladas JG, Bahadur GG, Al-Hashimi S, Pineda R. A review of machine learning techniques for keratoconus detection and refractive surgery screening. *Semin Ophthalmol* 2019;34:317–26. <https://doi.org/10.1080/08820538.2019.1620812>.
- [185] Issarti I, Consejo A, Jiménez-García M, Kreps EO, Koppen C, Rozema JJ. Logistic index for keratoconus detection and severity scoring (Logik). *Comput Biol Med* 2020;122:103809. <https://doi.org/10.1016/j.combiomed.2020.103809>.
- [186] Zéboulon P, Debellemanière G, Bouvet M, Gatinel D. Corneal topography raw data classification using a convolutional neural network. *Am J Ophthalmol* 2020; 219:33–9. <https://doi.org/10.1016/j.ajo.2020.06.005>.
- [187] Castro-Luna GM, Martínez-Finkelshtein A, Ramos-López D. Robust keratoconus detection with Bayesian network classifier for Placido-based corneal indices. *Contact Lens Anterior Eye* 2020;43:366–72. <https://doi.org/10.1016/j.clae.2019.12.006>.
- [188] Kovács I, Miháltz K, Kránitz K, Juhász É, Takács Á, Dienes L, et al. Accuracy of machine learning classifiers using bilateral data from a Scheimpflug camera for identifying eyes with preclinical signs of keratoconus. *J Cataract Refract Surg* 2016;42:275–83. <https://doi.org/10.1016/j.jcrs.2015.09.020>.
- [189] Hidalgo IR, Rodriguez P, Rozema JJ, Dhubhghaill SN, Zakaria N, Tassignon MJ, et al. Evaluation of a machine-learning classifier for keratoconus detection based on Scheimpflug tomography. *Cornea* 2016;35:827–32. <https://doi.org/10.1097/ICO.0000000000000834>.
- [190] Lavric A, KeratoDetect VP. Keratoconus detection algorithm using convolutional neural networks. *Comput Intell Neurosci* 2019;8162567. <https://doi.org/10.1155/2019/8162567>.
- [191] Accardo PA, Pensiero S. Neural network-based system for early keratoconus detection from corneal topography. *J Biomed Inform* 2002;35:151–9. [https://doi.org/10.1016/S1532-0464\(02\)00513-0](https://doi.org/10.1016/S1532-0464(02)00513-0).
- [192] Kamiya K, Ayatsuka Y, Kato Y, Fujimura F, Takahashi M, Shoji N, et al. Keratoconus detection using deep learning of colour-coded maps with anterior segment optical coherence tomography: a diagnostic accuracy study. *BMJ Open* 2019;9:e031313. <https://doi.org/10.1136/bmjopen-2019-031313>.
- [193] dos Santos VA, Schmetterer L, Stegmann H, Pfister M, Messner A, Schmindinger G, et al. CorneaNet: fast segmentation of cornea OCT scans of healthy and keratoconic eyes using deep learning. *Biomed Opt Express* 2019;10:622. <https://doi.org/10.1364/boe.10.000622>.
- [194] Yousefi S, Yousefi E, Takahashi H, Hayashi T, Tampo H, Inoda S, et al. Keratoconus severity identification using unsupervised machine learning. *PLoS ONE* 2019;13:e0205998. <https://doi.org/10.1371/journal.pone.0205998>.
- [195] Shi C, Wang M, Zhu T, Zhang Y, Ye Y, Jiang J, et al. Machine learning helps improve diagnostic ability of subclinical keratoconus using Scheimpflug and OCT imaging modalities. *Eye Vis* 2020;7. <https://doi.org/10.1186/s40662-020-00213-3>.
- [196] Smadja D, Touboul D, Cohen A, Doveh E, Santhiago MR, Mello GR, et al. Detection of subclinical keratoconus using an automated decision tree classification. *Am J Ophthalmol* 2013;156:237–46. <https://doi.org/10.1016/j.ajo.2013.03.034>.
- [197] Smolek MK, Klyce SD. Current keratoconus detection methods compared with a neural network approach. *Investig Ophthalmol Vis Sci* 1997;38:2290–9.
- [198] Saad A, Gatinel D. Evaluation of total and corneal wavefront high order aberrations for the detection of forme fruste keratoconus. *Investig Ophthalmol Vis Sci* 2012;53:2978–92. <https://doi.org/10.1167/iovs.11-8803>.
- [199] Gobbe M, Guillon M. Corneal wavefront aberration measurements to detect keratoconus patients. *Contact Lens Anterior Eye* 2005;28:57–66. <https://doi.org/10.1016/j.clae.2004.12.001>.
- [200] Bühren J, Kühne C, Kohnen T. Defining subclinical keratoconus using corneal first-surface higher-order aberrations. *Am J Ophthalmol* 2007;143:381–9. <https://doi.org/10.1016/j.ajo.2006.11.062>.
- [201] Bühren J, Kook D, Yoon G, Kohnen T. Detection of subclinical keratoconus by using corneal anterior and posterior surface aberrations and thickness spatial profiles. *Investig Ophthalmol Vis Sci* 2010;51:3424–32. <https://doi.org/10.1167/iovs.09-4960>.
- [202] Xu Z, Li W, Jiang J, Zhuang X, Chen W, Peng M, et al. Characteristic of entire corneal topography and tomography for the detection of sub-clinical keratoconus with Zernike polynomials using Pentacam. *Sci Rep* 2017;7:1–10. <https://doi.org/10.1038/s41598-017-16568-y>.
- [203] Naderan M, Jahanrad A, Farjadnia M. Ocular, corneal, and internal aberrations in eyes with keratoconus, forme fruste keratoconus, and healthy eyes. *Int Ophthalmol* 2018;38:1565–73. <https://doi.org/10.1007/s10792-017-0620-5>.
- [204] Abdala-Figueroa A, Navas A, Ramirez-Miranda A, Lichtinger A, Hernandez-Bogantes E, Olivo-Payne A, et al. Scheimpflug and optical coherence tomography analysis of posterior keratoconus. *Cornea* 2016;35:1368–71. <https://doi.org/10.1097/ICO.0000000000000955>.
- [205] Ganesan N, Narayana S, Kasturi N, Kaliaperumal S, Srinivasan R, Vallinayagam M. Varied presentations of posterior keratoconus: a clinical case series. *Cornea* 2020;39:1348–53. <https://doi.org/10.1097/ICO.0000000000002455>.
- [206] Piñero DP, Alió JL, Alesón A, Escaf M, Miranda M. Pentacam posterior and anterior corneal aberrations in normal and keratoconic eyes. *Clin Exp Optom* 2009;92:297–303. <https://doi.org/10.1111/j.1444-0938.2009.00357.x>.
- [207] Chen M, Yoon G. Posterior corneal aberrations and their compensation effects on anterior corneal aberrations in keratoconic eyes. *Investig Ophthalmol Vis Sci* 2008;49:5645–52. <https://doi.org/10.1167/iovs.08-1874>.
- [208] Nakagawa T, Maeda N, Kosaki R, Hori Y, Inoue T, Saika M, et al. Higher-order aberrations due to the posterior corneal surface in patients with keratoconus. *Investig Ophthalmol Vis Sci* 2009;50:2660–5. <https://doi.org/10.1167/iovs.08-2754>.
- [209] Kosaki R, Maeda N, Bessho K, Hori Y, Nishida K, Suzuki A, et al. Magnitude and orientation of Zernike terms in patients with keratoconus. *Investig Ophthalmol Vis Sci* 2007;48:3062–8. <https://doi.org/10.1167/iovs.06-1285>.
- [210] Gordon-Shaag A, Millodot M, Ifrah R, Shneor E. Aberrations and topography in normal, keratoconus-suspect, and keratoconic eyes. *Optom Vis Sci* 2012;89: 411–8. <https://doi.org/10.1097/OPX.0b013e318249d727>.
- [211] Lim L, Wei RH, Chan WK, Tan DTH. Evaluation of higher order ocular aberrations in patients with keratoconus. *J Refract Surg* 2007;23:825–8. <https://doi.org/10.3928/1081-597x-20071001-13>.
- [212] Jafri B, Li X, Yang H, Rabinowitz YS. Higher order wavefront aberrations and topography in early and suspected keratoconus. *J Refract Surg* 2007;23:774–81. <https://doi.org/10.3928/1081-597x-20071001-06>.
- [213] Vellara HR, Patel DV. Biomechanical properties of the keratoconic cornea: A review. *Clin Exp Optom* 2015;98:31–8. <https://doi.org/10.1111/coo.12211>.
- [214] Masiwa LE, Moodley V. A review of corneal imaging methods for the early diagnosis of pre-clinical keratoconus. *J Optom* 2020;13:269–75. <https://doi.org/10.1016/j.joptom.2019.11.001>.
- [215] Nash IS, Greene PR, Foster CS. Comparison of mechanical properties of keratoconus and normal corneas. *Exp Eye Res* 1982;35:413–24. [https://doi.org/10.1016/0014-4835\(82\)90040-9](https://doi.org/10.1016/0014-4835(82)90040-9).
- [216] Andreassen TT, Hjorth Simonsen A, Oxlund H. Biomechanical properties of keratoconus and normal corneas. *Exp Eye Res* 1980;31:435–41. [https://doi.org/10.1016/S0014-4835\(80\)80027-3](https://doi.org/10.1016/S0014-4835(80)80027-3).
- [217] Scarcelli G, Besner S, Pineda R, Yun SH. Biomechanical characterization of keratoconus corneas ex vivo with Brillouin microscopy. *Investig Ophthalmol Vis Sci* 2014;55:4490–5. <https://doi.org/10.1167/iovs.14-14450>.
- [218] Luce DA. Determining in vivo biomechanical properties of the cornea with an ocular response analyzer. *J Cataract Refract Surg* 2005;31:156–62. <https://doi.org/10.1016/j.jcrs.2004.10.044>.
- [219] Shetty R, Francis M, Shroff R, Pahuja N, Khamar P, Girissh M, et al. Corneal biomechanical changes and tissue remodeling after SMILE and LASIK. *Investig Ophthalmol Vis Sci* 2017;58:5703–12. <https://doi.org/10.1167/iovs.17-22864>.
- [220] Yenerel NM, Kucumen RB, Gorgun E. Changes in corneal biomechanics in patients with keratoconus after penetrating keratoplasty. *Cornea* 2010;29:1247–51. <https://doi.org/10.1097/ICO.0b013e3181ca6383>.
- [221] Vinciguerra R, Ambrósio R, Roberts CJ, Azzolini C, Vinciguerra P. Biomechanical characterization of subclinical keratoconus without topographic or tomographic abnormalities. *J Refract Surg* 2017;33:399–407. <https://doi.org/10.3928/1081597X-20170213-01>.
- [222] Steinberg J, Katz T, Lücke K, Frings A, Druchkiv V, Linke SJ. Screening for keratoconus with new dynamic biomechanical in vivo Scheimpflug analyses. *Cornea* 2015;34:1404–12. <https://doi.org/10.1097/ICO.0000000000000598>.
- [223] Saad A, Lteif Y, Azan E, Gatinel D. Biomechanical properties of keratoconus suspect eyes. *Invest Ophthalmol Vis Sci* 2010;51:2912–6. <https://doi.org/10.1167/iovs.09-4304>.
- [224] Ali NQ, Patel DV, McGhee CNJ. Biomechanical responses of healthy and keratoconic corneas measured using a noncontact Scheimpflug-based tonometer. *Invest Ophthalmol Vis Sci* 2014;55:3651–9. <https://doi.org/10.1167/iovs.13-13715>.
- [225] Fontes BM, Ambrósio R, Jardim D, Velarde GC, Nosé W. Corneal biomechanical metrics and anterior segment parameters in mild keratoconus. *Ophthalmology* 2010;117:673–9. <https://doi.org/10.1016/j.ophtha.2009.09.023>.
- [226] Luz A, Lopes B, Hallahan KM, Valbon B, Fontes B, Schor P, et al. Discriminant value of custom ocular response analyzer waveform derivatives in forme fruste keratoconus. *Am J Ophthalmol* 2016;164:14–21. <https://doi.org/10.1016/j.ajo.2015.12.020>.
- [227] Catalán-López S, Cadarso-Suárez L, López-Ratón M, Cadarso-Suárez C. Corneal biomechanics in unilateral keratoconus and fellow eyes with a Scheimpflug-based

- tonometer. *Optom Vis Sci* 2018;95:608–15. <https://doi.org/10.1097/OPX.0000000000001241>.
- [228] De Stefano VS, Ford MR, Seven I, Dupps WJ. Depth-dependent corneal biomechanical properties in normal and keratoconus subjects by optical coherence elastography. *Transl Vis Sci Technol* 2020;9:4. <https://doi.org/10.1167/tvst.9.7.4>.
- [229] Jesus DA, Iskander DR. Assessment of corneal properties based on statistical modeling of OCT speckle. *Biomed Opt Express* 2017;8:162. <https://doi.org/10.1364/boe.8.000162>.
- [230] McMahon TT, Szczołka-Flynn L, Barr JT, Anderson RJ, Slaughter ME, Lass JH, et al. A new method for grading the severity of keratoconus: The Keratoconus Severity Score (KSS). *Cornea* 2006;25:794–800. <https://doi.org/10.1097/01.icc.0000226359.26678.d1>.
- [231] Perry HD, Buxton JN, Fine BS. Round and oval cones in keratoconus. *Ophthalmology* 1980;87:905–9. [https://doi.org/10.1016/S0161-6420\(80\)35145-2](https://doi.org/10.1016/S0161-6420(80)35145-2).
- [232] Vega Estrada A, Sanz Díez P, Alió JL. Keratoconus grading and its therapeutic implications. In: Alió J. (eds) *Keratoconus. Essentials in ophthalmology*, 2017, p. 177–84. doi: 10.1007/978-3-319-43881-8_15.
- [233] Amsler M. Kératocône classique et kératocône fruste; arguments unitaires. *Ann Ocul (Paris)* 1947;180:112. <https://doi.org/10.1159/000300309>.
- [234] Peña-García P, Sanz-Díez P, Durán-García ML. Keratoconus management guidelines. *Int J Keratoconus Ectatic Corneal Dis* 2015;4:1–39. <https://doi.org/10.5005/jp-journals-10025-1095>.
- [235] Alió JL, Shabayek MH. Corneal higher order aberrations: A method to grade keratoconus. *J Refract Surg* 2006;22:539–45. <https://doi.org/10.3928/1081-597x-20060601-05>.
- [236] Kandel H, Pesudovs K, Watson SL. Measurement of quality of life in keratoconus. *Cornea* 2020;39:386–93. <https://doi.org/10.1097/ICO.0000000000002170>.
- [237] Alió JL, Piñero DP, Alesón A, Teus MA, Barraquer RI, Murta J, et al. Keratoconus-integrated characterization considering anterior corneal aberrations, internal astigmatism, and corneal biomechanics. *J Cataract Refract Surg* 2011;37:552–68. <https://doi.org/10.1016/j.jcrs.2010.10.046>.
- [238] Belin MW, Duncan JK. Keratoconus: The ABCD grading system. *Klin Monbl Augenheilkd* 2016;233:701–7. <https://doi.org/10.1055/s-0042-100626>.
- [239] Piñero DP, Alió JL, Alesón A, Vergara ME, Miranda M. Corneal volume, pachymetry, and correlation of anterior and posterior corneal shape in subclinical and different stages of clinical keratoconus. *J Cataract Refract Surg* 2010;36:814–25. <https://doi.org/10.1016/j.jcrs.2009.11.012>.
- [240] Shetty R, Rao H, Khamar P, Sainani K, Vunnava K, Jayadev C, et al. Keratoconus screening indices and their diagnostic ability to distinguish normal from ectatic corneas. *Am J Ophthalmol* 2017;181:140–8. <https://doi.org/10.1016/j.ajo.2017.06.031>.
- [241] Wilson SE, Lin DTC, Klyce SD. Corneal topography of keratoconus. *Cornea* 1991;10:2–8. <https://doi.org/10.1097/00003226-199101000-00002>.
- [242] Dingeldein SA, Klyce SD, Wilson SE. Quantitative descriptors of corneal shape derived from computer-assisted analysis of photokeratographs. *Refract Corneal Surg* 1989;5:372–8. <https://doi.org/10.3928/1081-597x-19891101-06>.
- [243] Gharieb HM, Othman IS, Oreaba AH, Abdelatif MK. Topographic, elevation, and keratoconus indices for diagnosis of keratoconus by a combined Placido and Scheimpflug topography system. *Eur J Ophthalmol* 2021;31:1553–62. <https://doi.org/10.1177/1120672121991725>.
- [244] Toprak I, Yaylali V, Yildirim C. A combination of topographic and pachymetric parameters in keratoconus diagnosis. *Cont Lens Anterior Eye* 2015;38:357–62. <https://doi.org/10.1016/j.clae.2015.04.001>.
- [245] Rabinowitz YS, Rasheed K. KISA% index: A quantitative videokeratography algorithm embodying minimal topographic criteria for diagnosing keratoconus. *J Cataract Refract Surg* 1999;25:1327–35. [https://doi.org/10.1016/S0886-3350\(99\)00195-9](https://doi.org/10.1016/S0886-3350(99)00195-9).
- [246] Belin MW, Ambrósio R. Scheimpflug imaging for keratoconus and ectatic disease. *Indian J Ophthalmol* 2013;61:401–6. <https://doi.org/10.4103/0301-4738.1166059>.
- [247] Kreps EO, Jimenez-García M, Issarti I, Claerhout I, Koppen C, Rozema JJ. Repeatability of the Pentacam HR in various grades of keratoconus. *Am J Ophthalmol* 2020;219:154–62. <https://doi.org/10.1016/j.ajo.2020.06.013>.
- [248] Sahabjada S, Al-Mahrouqi HH, Moshegov S, Panchatcharam SM, Chan E, Daniell M, et al. Eye rubbing in the aetiology of keratoconus: a systematic review and meta-analysis. *Graefes Arch Clin Exp Ophthalmol* 2021;259:2057–67. <https://doi.org/10.1007/s00417-021-05081-8>.
- [249] McMonnies CW. Eye rubbing type and prevalence including contact lens ‘removal-relief’ rubbing. *Clin Exp Optom* 2016;99:366–72. <https://doi.org/10.1111/cxo.12343>.
- [250] Abass A, Lopes BT, Jones S, White L, Clamp J, Elsheikh A. Non-orthogonal refractive lenses for non-orthogonal astigmatic eyes. *Curr Eye Res* 2019;44:781–9. <https://doi.org/10.1080/02713683.2019.1589523>.
- [251] Rico-Del-Viejo L, García-Montero M, Hernández-Verdejo JL, García-Lázaro S, Gómez-Sanz FJ, Lorente-Velázquez A. Nonsurgical procedures for keratoconus management. *J Ophthalmol* 2017;97:70650. <https://doi.org/10.1155/2017/9707650>.
- [252] García-Lledo M, Feinbaum C, Alió JL. Contact lens fitting in keratoconus. *Compr Ophthalmol Update* 2006;7:47–52.
- [253] Şengör T, Kurna SA. Update on contact lens treatment of keratoconus. *Turkish J Ophthalmol* 2020;50:234–44. <https://doi.org/10.4274/tjo.galenos.2020.70481>.
- [254] Lim L, Lim EWL. Current perspectives in the management of keratoconus with contact lenses. *Eye* 2020;34:2175–96. <https://doi.org/10.1038/s41433-020-1065-z>.
- [255] Lim N, Vogt U. Characteristics and functional outcomes of 130 patients with keratoconus attending a specialist contact lens clinic. *Eye* 2002;16:54–9. <https://doi.org/10.1038/sj.eye.6700061>.
- [256] Saraç Ö, Kars ME, Temel B, Çağıl N. Clinical evaluation of different types of contact lenses in keratoconus management. *Contact Lens Anterior Eye* 2019;42:482–6. <https://doi.org/10.1016/j.clae.2019.02.013>.
- [257] Romero-Jiménez M, Santodomingo-Rubido J, González-Méjome JM. An assessment of the optimal lens fit rate in keratoconus subjects using three-point-touch and apical touch fitting approaches with the rose K2 lens. *Eye Contact Lens* 2013;39:269–72. <https://doi.org/10.1097/ICL.0b013e318295b4f4>.
- [258] Romero-Jiménez M, Santodomingo-Rubido J, Flores-Rodríguez P, González-Méjome JM. Short-term corneal changes with gas-permeable contact lens wear in keratoconus subjects: a comparison of two fitting approaches. *J Optom* 2015;8:48–55. <https://doi.org/10.1016/j.optom.2014.07.007>.
- [259] McMonnies CW. Keratoconus fittings: Apical clearance or apical support? *Eye Contact Lens* 2004;30:147–55. <https://doi.org/10.1097/01.ICL.0000138717.57592.36>.
- [260] Edrington TB, Gundel RE, Libassi DP, Wagner H, Pierce GE, Walline JJ, et al. Variables affecting rigid contact lens comfort in the collaborative longitudinal evaluation of keratoconus (CLEK) study. *Optom Vis Sci* 2004;81:182–8. <https://doi.org/10.1097/00006324-200403000-00010>.
- [261] Zadnik K, Barr JT, Steger-May K, Edrington TB, McMahon TT, Gordon MO. Comparison of flat and steep rigid contact lens fitting methods in keratoconus. *Optom Vis Sci* 2005;82:1014–21. <https://doi.org/10.1097/01.opx.0000192349.11525.de>.
- [262] Betts AM, Mitchell GL, Zadnik K. Visual performance and comfort with the Rose K lens for keratoconus. *Optom Vis Sci* 2002;79:493–501. <https://doi.org/10.1097/00006324-200208000-00011>.
- [263] Jae LL, Kim MK. Clinical performance and fitting characteristics with a multicurve lens for keratoconus. *Eye Contact Lens* 2004;30:20–4. <https://doi.org/10.1097/01.ICL.0000095230.24618.03>.
- [264] Hu CY, Tung HC. Managing keratoconus with reverse-geometry and dual-geometry contact lenses: A case report. *Eye Contact Lens* 2008;34:71–5. <https://doi.org/10.1097/ICL.0b013e31805e35fa>.
- [265] Jaworski P, Wyględowska-Promieńska D, Gierek-Ciaciura S. Application of duo-systems (piggy back) in correction of keratoconus. *Klin Oczna* 2004;106:629–32.
- [266] O'Donnell C, Maldonado-Codina C. A hyper-Dk piggyback contact lens system for keratoconus. *Eye Contact Lens* 2004;30:44–8. <https://doi.org/10.1097/01.ICL.0000104596.50832.7F>.
- [267] Romero-Jiménez M, Santodomingo-Rubido J, Flores-Rodríguez P, González-Méjome JM. Which soft contact lens power is better for piggyback fitting in keratoconus? *Contact Lens Anterior Eye* 2013;36:45–8. <https://doi.org/10.1016/j.clae.2012.10.070>.
- [268] Romero-Jiménez M, Santodomingo-Rubido J, González-Méjome JM, Flores-Rodríguez P, Villa-Collar C. Which soft lens power is better for piggyback in keratoconus? Part II. *Contact Lens Anterior Eye* 2015;38:48–53. <https://doi.org/10.1016/j.clae.2014.09.012>.
- [269] De Luis EB, Etxebarria Ecnarro J, Santamaría Carro A, Feijoo LR. Irregular corneas: Improve visual function with scleral contact lenses. *Eye Contact Lens* 2018;44:159–63. <https://doi.org/10.1097/ICL.0000000000000340>.
- [270] Downie LE, Lindsay RG. Contact lens management of keratoconus. *Clin Exp Optom* 2015;98:299–311. <https://doi.org/10.1111/cxo.12300>.
- [271] Lindsay R. Pellucid marginal degeneration. *Clin Exp Optom* 1993;76:219–21. <https://doi.org/10.1111/j.1444-0938.1993.tb03061.x>.
- [272] Porcar E, Montalt JC, España-Gregori E, Peris-Martínez C. Fitting scleral lenses less than 15 mm in diameter: A review of the literature. *Eye Contact Lens* 2020;46:63–9. <https://doi.org/10.1097/ICL.0000000000000647>.
- [273] Alonso-Caneiro D, Vincent SJ, Collins MJ. Morphological changes in the conjunctiva, episclera and sclera following short-term miniscleral contact lens wear in rigid lens neophytes. *Cont Lens Anterior Eye* 2016;39:53–61. <https://doi.org/10.1016/j.clae.2015.06.008>.
- [274] Fisher D, Collins MJ, Vincent SJ. Fluid reservoir thickness and corneal oedema during closed eye scleral lens wear. *Cont Lens Anterior Eye* 2021;44:102–7. <https://doi.org/10.1016/j.clae.2020.08.002>.
- [275] Fisher D, Collins MJ, Vincent SJ. Fluid reservoir thickness and corneal edema during open-eye scleral lens wear. *Optom Vis Sci* 2020;97:683–9. <https://doi.org/10.1097/OPX.0000000000001558>.
- [276] Kumar M, Shetty R, Lalgudi VG, Atchison DA, Vincent SJ. Corneal ectasia with Stevens-Johnson syndrome. *Clin Exp Optom* 2021;104:535–7. <https://doi.org/10.1080/08164622.2021.1878835>.
- [277] Kumar M, Shetty R, Dutta D, Rao HL, Jayadev C, Atchison DA. Effects of a semi-scleral contact lens on refraction and higher order aberrations. *Cont Lens Anterior Eye* 2019;42:670–4. <https://doi.org/10.1016/j.clae.2019.06.002>.
- [278] Porcar E, España E, Montalt JC, Benlloch-Fornés JJ, Peris-Martínez C. Post-LASIK visual quality with a corneoscleral contact lens to treat irregular corneas. *Eye Contact Lens* 2017;43:46–50. <https://doi.org/10.1097/ICL.0000000000000231>.
- [279] Montalt JC, Porcar E, España-Gregori E, Peris-Martínez C. Corneoscleral contact lenses for visual rehabilitation after keratoplasty surgery. *Cont Lens Anterior Eye* 2020;43:589–94. <https://doi.org/10.1016/j.clae.2020.04.009>.
- [280] Porcar E, Montalt JC, España-Gregori E, Peris-Martínez C. Impact of corneoscleral contact lens usage on corneal biomechanical parameters in keratoconic eyes. *Eye Contact Lens* 2019;45:318–23. <https://doi.org/10.1097/ICL.0000000000000579>.
- [281] de Luis EB, Acera A, Santamaría Carro A, Feijoo Lera R, Escudero Argaluz J, Etxebarria EJ. Changes in the corneal thickness and limbus after 1 year of scleral

- contact lens use. *Eye* 2020;34:1654–61. <https://doi.org/10.1038/s41433-019-0729-z>.
- [282] Michaud L, Lipson M, Kramer E, Walker M. The official guide to scleral lens terminology. *Cont Lens Anterior Eye* 2020;43:529–34. <https://doi.org/10.1016/j.clae.2019.09.006>.
- [283] Ling JJ, Mian SI, Stein JD, Rahman M, Poliskey J, Woodward MA. Impact of scleral contact lens use on the rate of corneal transplantation for keratoconus. *Cornea* 2021;40:39–42. <https://doi.org/10.1097/ICO.0000000000002388>.
- [284] Koppen C, Kreps EO, Anthonissen L, Van Hoey M, Dhuhghail SN, Vermeulen L. Scleral lenses reduce the need for corneal transplants in severe keratoconus. *Am J Ophthalmol* 2018;185:43–7. <https://doi.org/10.1016/j.ajo.2017.10.022>.
- [285] Segal O, Barkana Y, Hourovitz D, Behrman S, Kamun Y, Avni I, et al. Scleral contact lenses may help where other modalities fail. *Cornea* 2003;22:308–10. <https://doi.org/10.1097/00003226-200305000-00006>.
- [286] Rosenthal P, Croteau A. Fluid-ventilated, gas-permeable scleral contact lens is an effective option for managing severe ocular surface disease and many corneal disorders that would otherwise require penetrating keratoplasty. *Eye Contact Lens* 2005;31:130–4. <https://doi.org/10.1097/01.ICL.0000152492.98553.8D>.
- [287] Vincent SJ. The rigid lens renaissance: a surge in sclerals. *Cont Lens Anterior Eye* 2018;41:139–43. <https://doi.org/10.1016/j.clae.2018.01.003>.
- [288] Woods CA, Efron N, Morgan P. Are eye-care practitioners fitting scleral contact lenses? *Clin Exp Optom* 2020;103:449–53. <https://doi.org/10.1111/cxo.13105>.
- [289] Vincent SJ, Alonso-Caneiro D, Collins MJ, Beanland A, Lam L, Lim CC, et al. Hypoxic corneal changes following eight hours of scleral contact lens wear. *Optom Vis Sci* 2016;93:293–9. <https://doi.org/10.1097/OPX.0000000000000803>.
- [290] Giasson CJ, Morency J, Melillo M, Michaud L. Oxygen tension beneath scleral lenses of different clearances. *Optom Vis Sci* 2017;94:466–75. <https://doi.org/10.1097/OPX.0000000000001038>.
- [291] Tan B, Tse V, Kim YH, Lin K, Zhou Y, Lin MC. Effects of scleral-lens oxygen transmissibility on corneal thickness: A pilot study. *Cont Lens Anterior Eye* 2019;42:366–72. <https://doi.org/10.1016/j.clae.2019.04.002>.
- [292] Vincent SJ, Alonso-Caneiro D, Collins MJ. The time course and nature of corneal oedema during sealed miniscleral contact lens wear. *Cont Lens Anterior Eye* 2019;42:49–54. <https://doi.org/10.1016/j.clae.2018.03.001>.
- [293] Esen F, Tokar E. Influence of apical clearance on mini-scleral lens settling, clinical performance, and corneal thickness changes. *Eye Contact Lens* 2017;43:230–5. <https://doi.org/10.1097/ICL.0000000000000266>.
- [294] Kumar M, Shetty R, Khamar P, Vincent SJ. Scleral lens-induced corneal edema after penetrating keratoplasty. *Optom Vis Sci* 2020;97:697–702. <https://doi.org/10.1097/OPX.0000000000001571>.
- [295] Paugh JR, Chen E, Heinrich C, Miller H, Gates T, Nguyen AL, et al. Silicone hydrogel and rigid gas-permeable scleral lens tear exchange. *Eye Contact Lens* 2018;44:97–101. <https://doi.org/10.1097/icl.0000000000000400>.
- [296] Tse V, Tan B, Kim YH, Zhou Y, Lin MC. Tear dynamics under scleral lenses. *Cont Lens Anterior Eye* 2019;42:43–8. <https://doi.org/10.1016/j.clae.2018.11.016>.
- [297] Tan B, Zhou Y, Yuen TL, Lin K, Michaud L, Lin MC. Effects of scleral-lens tear clearance on corneal edema and post-lens tear dynamics: A pilot study. *Optom Vis Sci* 2018;95:481–90. <https://doi.org/10.1097/OPX.0000000000001220>.
- [298] Macedo-de-Araújo RJ, van der Worp E, González-Méjome JM. A one-year prospective study on scleral lens wear success. *Cont Lens Anterior Eye* 2020;43:553–61. <https://doi.org/10.1016/j.clae.2019.10.140>.
- [299] Walker MK, Bergmanson JP, Miller WL, Marsack JD, Johnson LA. Complications and fitting challenges associated with scleral contact lenses: A review. *Cont Lens Anterior Eye* 2016;39:88–96. <https://doi.org/10.1016/j.clae.2015.08.003>.
- [300] Schornack MM, Focht J, Harthan J, Nau CB, Nau A, Cao D, et al. Factors associated with patient-reported midday fogging in established scleral lens wearers. *Cont Lens Anterior Eye* 2020;43:602–8. <https://doi.org/10.1016/j.clae.2020.03.005>.
- [301] Soeters N, Visser ES, Imhof SM, Tahzib NG. Scleral lens influence on corneal curvature and pachymetry in keratoconus patients. *Cont Lens Anterior Eye* 2015;38:294–7. <https://doi.org/10.1016/j.clae.2015.03.006>.
- [302] Serramito-Blanco M, Carpena-Torres C, Carballo J, Piñero D, Lipson M, Carracedo G. Anterior corneal curvature and aberration changes after scleral lens wear in keratoconus patients with and without ring segments. *Eye Contact Lens* 2019;45:141–8. <https://doi.org/10.1097/ICL.0000000000000534>.
- [303] Severinsky B, Fadel D, Davelman J, Moulton E. Effect of scleral lenses on corneal topography in keratoconus: a case series of cross-linked versus non-cross-linked eyes. *Cornea* 2019;38:986–91. <https://doi.org/10.1097/ICO.0000000000002008>.
- [304] Kumar M, Shetty R, Lalgudi VG, Vincent SJ. Scleral lens wear following penetrating keratoplasty: changes in corneal curvature and optics. *Ophthalmic Physiol Opt* 2020;40:502–9. <https://doi.org/10.1111/opo.12693>.
- [305] Vincent SJ, Alonso-Caneiro D, Collins MJ. Corneal changes following short-term miniscleral contact lens wear. *Cont Lens Anterior Eye* 2014;37:461–8. <https://doi.org/10.1016/j.clae.2014.08.002>.
- [306] Vincent SJ, Alonso-Caneiro D, Collins MJ. Miniscleral lens wear influences corneal curvature and optics. *Ophthalmic Physiol Opt* 2016;36:100–11. <https://doi.org/10.1111/opo.12270>.
- [307] Jinabhai A, O'Donnell C, Radhakrishnan H. Changes in refraction, ocular aberrations, and corneal structure after suspending rigid gas-permeable contact lens wear in keratoconus. *Cornea* 2012;31:500–8. <https://doi.org/10.1097/ICO.0b013e31820f777b>.
- [308] Pullum KW, Buckley RJ. A study of 530 patients referred for rigid gas permeable scleral contact lens assessment. *Cornea* 1997;16:612–22. <https://doi.org/10.1097/00003226-199711000-00003>.
- [309] Salam A, Melia B, Singh AJ. Scleral contact lenses are not optically inferior to corneal lenses. *Br J Ophthalmol* 2005;89:1662–3. <https://doi.org/10.1136/bjo.2005.074377>.
- [310] Bergmanson JPG, Walker MK, Johnson LA. Assessing scleral contact lens satisfaction in a keratoconus population. *Optom Vis Sci* 2016;93:855–60. <https://doi.org/10.1097/OPX.0000000000000882>.
- [311] Kumar P, Bandela PK, Bharadwaj SR. Do visual performance and optical quality vary across different contact lens correction modalities in keratoconus? *Cont Lens Anterior Eye* 2020;43:568–76. <https://doi.org/10.1016/j.clae.2020.03.009>.
- [312] Levit A, Benwell M, Evans BJW. Randomised controlled trial of corneal vs. scleral rigid gas permeable contact lenses for keratoconus and other ectatic corneal disorders. *Cont Lens Anterior Eye* 2020;43:543–52. <https://doi.org/10.1016/j.clae.2019.12.007>.
- [313] Gumus K, Gire A, Pflugfelder SC. The impact of the Boston ocular surface prosthesis on wavefront higher-order aberrations. *Am J Ophthalmol* 2011;151:682–690.e2. <https://doi.org/10.1016/j.ajo.2010.10.027>.
- [314] Hussoin T, Le HG, Carrasquillo KG, Johns L, Rosenthal P, Jacobs DS. The effect of optic asphericity on visual rehabilitation of corneal ectasia with a prosthetic device. *Eye Contact Lens* 2012;38:300–5. <https://doi.org/10.1097/ICL.0b013e3182657da5>.
- [315] Sabesan R, Johns L, Tomashevskaya O, Jacobs DS, Rosenthal P, Yoon G. Wavefront-guided scleral lens prosthetic device for keratoconus. *Optom Vis Sci* 2013;90:314–23. <https://doi.org/10.1097/OPX.0b013e318288d19c>.
- [316] Jinabhai AN. Customised aberration-controlling corrections for keratoconic patients using contact lenses. *Clin Exp Optom* 2020;103. <https://doi.org/10.1111/cxo.12937>.
- [317] Yilmaz I, Ozelcik F, Basarir B, Demir G, Durusoy G, Taskapili M. Clinical performance of toris K contact lens in patients with moderate to advanced keratoconus: A real life retrospective analysis. *J Ophthalmol* 2016;2358901. <https://doi.org/10.1155/2016/2358901>.
- [318] Sultan P, Dogan C, Iskeleli G. A retrospective analysis of vision correction and safety in keratoconus patients wearing Toris K soft contact lenses. *Int Ophthalmol* 2016;36:799–805. <https://doi.org/10.1007/s10792-016-0200-0>.
- [319] Gumus K, Kahraman N. A new fitting approach for providing adequate comfort and visual performance in keratoconus: Soft HydroCone (Toris K) lenses. *Eye Contact Lens* 2016;42:225–30. <https://doi.org/10.1097/ICL.0000000000000183>.
- [320] Altun A, Kurma SA, Sengor T, Altun G, Olcaysi OO, Simsek MH. Success of hydrocone (TORIS-K) soft contact lens for keratoconus and traumatic keratopathy. *Pakistan J Med Sci* 2015;31:995–8. <https://doi.org/10.12669/pjms.314.6125>.
- [321] Yildiz EH, Erdurmus M, Elibol ES, Acar B, Vural ET. Contact lens impact on quality of life in keratoconus patients: Rigid gas permeable versus soft silicone-hydrogel keratoconus lenses. *Int J Ophthalmol* 2015;8:1074–7. <https://doi.org/10.3980/j.issn.2222-3959.2015.05.38>.
- [322] Carballo-Alvarez J, Puell MC, Cuñía R, Diaz-Valle D, Vazquez JM, Benitez-del-Castillo JM. Soft contact lens fitting after intrastromal corneal ring segment implantation to treat keratoconus. *Cont Lens Anterior Eye* 2014;37:377–81. <https://doi.org/10.1016/j.clae.2014.06.001>.
- [323] Fernández-Velázquez FJ, Fernández-Fidalgo MJ. Feasibility of custom-made hydrogel contact lenses in keratoconus with previous implantation of intracorneal ring segments. *Cont Lens Anterior Eye* 2015;38:351–6. <https://doi.org/10.1016/j.clae.2015.03.016>.
- [324] Marsack JD, Parker KE, Applegate RA. Performance of wavefront-guided soft lenses in three keratoconus subjects. *Optom Vis Sci* 2008;85:E1172–8. <https://doi.org/10.1097/OPX.0b013e31818e8eaa>.
- [325] Sabesan R, Jeong TM, Carvalho L, Cox IG, Williams DR, Yoon G. Vision improvement by correcting higher-order aberrations with customized soft contact lenses in keratoconic eyes. *Opt Lett* 2007;32:1000. <https://doi.org/10.1364/ol.32.001000>.
- [326] Marsack JD, Parker KE, Niu Y, Pesudovs K, Applegate RA. On-eye performance of custom wavefront-guided soft contact lenses in a habitual soft lens-wearing keratoconic patient. *J Refract Surg* 2007;23:960–4. <https://doi.org/10.3928/1081-597x-20071101-18>.
- [327] Thibos LN, Hong X. Clinical applications of the Shack-Hartmann aberrometer. *Optom Vis Sci* 1999;76:817–25. <https://doi.org/10.1097/00006324-199912000-00016>.
- [328] Jinabhai A, Charman WN, O'Donnell C, Radhakrishnan H. Optical quality for keratoconic eyes with conventional RGP lens and simulated, customised contact lens corrections: A comparison. *Ophthalmic Physiol Opt* 2012;32:200–12. <https://doi.org/10.1111/j.1475-1313.2012.00904.x>.
- [329] Hashemi H, Beiranvand A, Yekta A, Maleki A, Yazdani N, Khabazkhoob M. Pentacam top indices for diagnosing subclinical and definite keratoconus. *J Curr Ophthalmol* 2016;28:21–6. <https://doi.org/10.1016/j.joco.2016.01.009>.
- [330] Negishi K, Kumanomido T, Utsumi Y, Tsubota K. Effect of higher-order aberrations on visual function in keratoconic eyes with a rigid gas permeable contact lens. *Am J Ophthalmol* 2007;144:924–9. <https://doi.org/10.1016/j.ajo.2007.08.004>.
- [331] Jinabhai A, O'Donnell C, Tromans C, Radhakrishnan H. Optical quality and visual performance with customised soft contact lenses for keratoconus. *Ophthalmic Physiol Opt* 2014;34:528–39. <https://doi.org/10.1111/opo.12133>.
- [332] Katsoulos C, Karageorgiadis L, Vasileiou N, Mousafiroopoulos T, Asimellis G. Customized hydrogel contact lenses for keratoconus incorporating correction for vertical coma aberration. *Ophthalmic Physiol Opt* 2009;29:321–9. <https://doi.org/10.1111/j.1475-1313.2009.00645.x>.

- [333] Suzuki A, Maeda N, Fuchihata M, Koh S, Nishida K, Fujikado T. Visual performance and optical quality of standardized asymmetric soft contact lenses in patients with keratoconus. *Invest Ophthalmol Vis Sci* 2017;58:2899–905. <https://doi.org/10.1167/iov.16-21296>.
- [334] De Brabander J, Chateau N, Marin G, Lopez-Gil N, Der Worp E, Van BA. Simulated optical performance of custom wavefront soft contact lenses for keratoconus. *Optom Vis Sci* 2003;80:637–43. <https://doi.org/10.1097/00006324-200309000-00008>.
- [335] Suzuki A, Koh S, Maeda N, Asonuma S, Santodomingo-Rubido J, Oie Y, et al. Optimizing correction of coma aberration in keratoconus with a novel soft contact lens. *Cont Lens Anterior Eye* 2021;44:101405. <https://doi.org/10.1016/j.clae.2020.12.071>.
- [336] Plainis S. Response to “Kerasoft IC compared to Rose-K in the management of corneal ectasias”. *Cont Lens Anterior Eye* 2013;36:153. <https://doi.org/10.1016/j.clae.2013.01.002>.
- [337] Rubinstein MP, Sud S. The use of hybrid lenses in management of the irregular cornea. *Cont Lens Anterior Eye* 1999;22:87–90. [https://doi.org/10.1016/S1367-0484\(99\)80044-7](https://doi.org/10.1016/S1367-0484(99)80044-7).
- [338] Leal F, Lipener C, Chalita MR, Uras R, Campos M, Höfling-Lima AL. Lente de contato de material híbrido em pacientes com ceratocone e astigmatismo miópico composto. *Arq Bras Oftalmol* 2007;70:247–54. <https://doi.org/10.1590/s0004-27492007000200012>.
- [339] Pilskalns B, Fink BA, Hill RM. Oxygen demands with hybrid contact lenses. *Optom Vis Sci* 2007;84:334–42. <https://doi.org/10.1097/OPX.0b013e3180421748>.
- [340] Morgan P, Woods CA, Tranoudis IG, Efron N, Jones L, Nlm B, et al. International contact lens prescribing in 2019. *Contact Lens Spectr* 2020;35:26–32.
- [341] Kloeck D, Koppen C, Kreps EO. Clinical outcome of hybrid contact lenses in keratoconus. *Eye Contact Lens* 2021;47:283–7. <https://doi.org/10.1097/ICL.0000000000000738>.
- [342] Dikmetas O, Kocabeyoglu S, Mogan MC. Evaluation of visual acuity outcomes and corneal alterations of new generation hybrid contact lenses in patients with advanced keratoconus. *Cornea* 2020;39:1366–70. <https://doi.org/10.1097/ICO.0000000000002438>.
- [343] Hassani M, Jafarzadehpour E, Mirzajani A, Yekta AA, Khabazkhoob M. A comparison of the visual acuity outcome between Clearkone and RGP lenses. *J Curr Ophthalmol* 2018;30:85–6. <https://doi.org/10.1016/j.joco.2017.08.006>.
- [344] Sorkin N, Varssano D. Corneal collagen crosslinking: A systematic review. *Ophthalmologica* 2014;232:10–27. <https://doi.org/10.1159/000357979>.
- [345] O’Brart DPS. Corneal collagen crosslinking for corneal ectasia: A review. *Eur J Ophthalmol* 2017;27:253–69. <https://doi.org/10.5301/ejo.5000916>.
- [346] Beckman KA, Gupta PK, Farid M, Berdahl JP, Yeu E, Ayres B, et al. Corneal crosslinking: Current protocols and clinical approach. *J Cataract Refract Surg* 2019;45:1670–9. <https://doi.org/10.1016/j.jcrs.2019.06.027>.
- [347] Santhiago MR, Randleman JB. The biology of corneal cross-linking derived from ultraviolet light and riboflavin. *Exp Eye Res* 2021;202. <https://doi.org/10.1016/j.exer.2020.108355>.
- [348] Spoerl E, Mrochen M, Sliney D, Trokel S, Seiler T. Safety of UVA-riboflavin cross-linking of the cornea. *Cornea* 2007;26:385–9. <https://doi.org/10.1097/ICO.0b013e3180334f78>.
- [349] Zhu AY, Jun AS, Soiberman US. Combined protocols for corneal collagen cross-linking with photorefractive surgery for refractive management of keratoconus: Update on techniques and review of literature. *Ophthalmol Ther* 2019;8:15–31. <https://doi.org/10.1007/s40123-019-00210-3>.
- [350] Liu Y, Liu Y, Zhang YN, Li AP, Zhang J, Liang QF, et al. Systematic review and meta-analysis comparing modified cross-linking and standard cross-linking for progressive keratoconus. *Int J Ophthalmol* 2017;10:1419–29. <https://doi.org/10.18240/ijo.2017.09.15>.
- [351] Wollensak G. Crosslinking treatment of progressive keratoconus: New hope. *Curr Opin Ophthalmol* 2006;17:356–60. <https://doi.org/10.1097/O1.icu.0000233954.86723.25>.
- [352] Raiskup-Wolf F, Hoyer A, Spoerl E, Pillunat LE. Collagen crosslinking with riboflavin and ultraviolet-A light in keratoconus: Long-term results. *J Cataract Refract Surg* 2008;34:796–801. <https://doi.org/10.1016/j.jcrs.2007.12.039>.
- [353] de Araujo BS, Kubo L, Marinho DR, Kwitko S. Keratoconus progression after intrastromal corneal ring segment implantation according to age: 5-year follow-up cohort study. *Int Ophthalmol* 2020;40:2847–54. <https://doi.org/10.1007/s10792-020-01468-4>.
- [354] Taşçı YY, Taşlıpınar G, Eyidoğan D, Saraç Ö, Çağlı N. Five-year long-term results of standard collagen cross-linking therapy in patients with keratoconus. *Turkish J Ophthalmol* 2020;50:200–5. <https://doi.org/10.4274/tjo.galenos.2020.53810>.
- [355] Singh T, Taneja M, Murthy S, Vaddavalli PK. Evaluation of safety and efficacy of different protocols of collagen cross linking for keratoconus. *Rom J Ophthalmol* 2020;64:158–67. <https://doi.org/10.22336/rjo.2020.28>.
- [356] Farhat R, Ghannam MK, Azar G, Nehme J, Sahyoun M, Hanna NG, et al. Safety, efficacy, and predictive factors of conventional epithelium-off corneal crosslinking in the treatment of progressive keratoconus. *J Ophthalmol* 2020;7487186. <https://doi.org/10.1155/2020/7487186>.
- [357] Marafon SB, Kwitko S, Marinho DR. Long-term results of accelerated and conventional corneal cross-linking. *Int Ophthalmol* 2020;40:2751–61. <https://doi.org/10.1007/s10792-020-01462-w>.
- [358] Arora R, Gupta D, Goyal JL, Jain P. Results of corneal collagen cross-linking in pediatric patients. *J Refract Surg* 2012;28. <https://doi.org/10.3928/1081597X-20121011-02>.
- [359] Chatzis N, Hafezi F. Progression of keratoconus and efficacy of corneal collagen cross-linking in children and adolescents. *J Refract Surg* 2012;28. <https://doi.org/10.3928/1081597X-20121011-01>.
- [360] Buzzonetti L, Petrocelli G. Transepithelial corneal cross-linking in pediatric patients: Early results. *J Refract Surg* 2012;28. <https://doi.org/10.3928/1081597X-20121011-03>.
- [361] Zotta PG, Moschou KA, Diakonis VF, Kymionis GD, Almaliotis DD, Karamitsos AP, et al. Corneal collagen cross-linking for progressive keratoconus in pediatric patients: a feasibility study. *J Refract Surg* 2012;28. <https://doi.org/10.3928/1081597X-20121011-08>.
- [362] Perez-Straziota C, Gaster RN, Rabinowitz YS. Corneal cross-linking for pediatric keratoconus review. *Cornea* 2018;37. <https://doi.org/10.1097/ICO.0000000000001579>.
- [363] Mandathara PS, Kalaiselvan P, Rathi VM, Murthy SI, Taneja M, Sangwan VS. Contact lens fitting after corneal collagen cross-linking. *Oman J Ophthalmol* 2019;12:177–80. <https://doi.org/10.4103/ojo.OJO.43.2018>.
- [364] Arance-Gil Á, Villa-Collar C, Pérez-Sánchez B, Carracedo G, Gutiérrez-Ortega R. Epithelium-off vs. transepithelial corneal collagen crosslinking in progressive keratoconus: 3 years of follow-up. *J Optom* 2021;14:189–98. <https://doi.org/10.1016/j.optom.2020.07.005>.
- [365] Godefrooij DA, Roohé SL, Soeters N, Wisse RPL. The independent effect of various cross-linking treatment modalities on treatment effectiveness in keratoconus. *Cornea* 2020;39:63–70. <https://doi.org/10.1097/ICO.0000000000002168>.
- [366] Chan CCK, Sharma M, Wachler BSB. Effect of inferior-segment Intacs with and without C3-R on keratoconus. *J Cataract Refract Surg* 2007;33:75–80. <https://doi.org/10.1016/j.jcrs.2006.09.012>.
- [367] Kankariya VP, Dube AB, Grentzelos MA, Kontadakis GA, Diakonis VF, Petrelli M, et al. Corneal cross-linking (CXL) combined with refractive surgery for the comprehensive management of keratoconus: CXL plus. *Indian J Ophthalmol* 2020;68:2757–72. <https://doi.org/10.4103/ijo.IJO.1841.20>.
- [368] Benoist D’Azy C, Pereira B, Chiambaretta F, Duthéil F. Efficacy of different procedures of intra-corneal ring segment implantation in keratoconus: a systematic review and meta-analysis. *Transl Vis Sci Technol* 2019;8:38. <https://doi.org/10.1167/tvst.8.3.38>.
- [369] Russo A, Faria-Correia F, Rechichi M, Festa G, Morescalchi F, Semeraro F. Topography/wavefront-guided photorefractive keratectomy combined with crosslinking for the treatment of keratoconus: preliminary results. *J Cataract Refract Surg* 2021;47:11–7. <https://doi.org/10.1097/j.jcrs.0000000000000359>.
- [370] Greenstein SA, Chung D, Rosato L, Gelles JD, Hersh PS. Corneal higher-order aberrations after crosslinking and intrastromal corneal ring segments for keratoconus. *J Cataract Refract Surg* 2020;46:979–85. <https://doi.org/10.1097/j.jcrs.0000000000000209>.
- [371] Pariselli C, Vega-Estrada A, Arnalich-Montiel F, Alio JL. Artificial neural network to guide intracorneal ring segments implantation for keratoconus treatment: a pilot study. *Eye Vis* 2020;7. <https://doi.org/10.1186/s40662-020-00184-5>.
- [372] Kim KH, Mian SI. Refractive approaches to visual rehabilitation in patients with keratoconus. *Curr Opin Ophthalmol* 2020;31:261–7. <https://doi.org/10.1097/ICU.0000000000000675>.
- [373] Fernández-Vega-Cueto L, Romano V, Zaldivar R, Gordillo CH, Aiello F, Madrid-Costa D, et al. Surgical options for the refractive correction of keratoconus: myth or reality. *J Ophthalmol* 2017;2017:7589816. <https://doi.org/10.1155/2017/7589816>.
- [374] Kasparova EA. Pathogenetic basis for treatment of primary keratoconus by a combined method of excimer laser surgery (combination of photorefractive and phototherapeutic keratectomy). *Vestn Oftalmol* 2002;118:21–215.
- [375] Bahar I, Levinger S, Kremer I. Wavefront-supported photorefractive keratectomy with the Bausch & Lomb Zyoptix in patients with myopic astigmatism and suspected keratoconus. *J Refract Surg* 2006;22:533–8. <https://doi.org/10.3928/1081-597x-20060601-04>.
- [376] Alpíns N, Stamatelatos G. Customized photoastigmatic refractive keratectomy using combined topographic and refractive data for myopia and astigmatism in eyes with forme fruste and mild keratoconus. *J Cataract Refract Surg* 2007;33:591–602. <https://doi.org/10.1016/j.jcrs.2006.12.014>.
- [377] Nosé W, Neves RA, Burris TE, Schanzlin DJ, Belfort R. Intrastromal corneal ring: 12-month sighted myopic eyes. *J Refract Surg* 1996;12:20–8. <https://doi.org/10.3928/1081-597x-19960101-08>.
- [378] Colin J, Cochener B, Savary G, Malet F. Correcting keratoconus with intracorneal rings. *J Cataract Refract Surg* 2000;26:1117–22. [https://doi.org/10.1016/S0886-3350\(00\)00451-X](https://doi.org/10.1016/S0886-3350(00)00451-X).
- [379] Coskunseven E, Kymionis GD, Tsiklis NS, Atun S, Arslan E, Jankov MR, et al. One-year results of intrastromal corneal ring segment implantation (KeraRing) using femtosecond laser in patients with keratoconus. *Am J Ophthalmol* 2008;145:775–9. <https://doi.org/10.1016/j.ajo.2007.12.022>.
- [380] Zare MA, Hashemi H, Salari MR. Intracorneal ring segment implantation for the management of keratoconus: Safety and efficacy. *J Cataract Refract Surg* 2007;33:1886–91. <https://doi.org/10.1016/j.jcrs.2007.06.055>.
- [381] Shabayek MH, Alió JL. Intrastromal corneal ring segment implantation by femtosecond laser for keratoconus correction. *Ophthalmology* 2007;114:1643–52. <https://doi.org/10.1016/j.ophtha.2006.11.033>.
- [382] Tomalla M, Cagnolati W. Modern treatment options for the therapy of keratoconus. *Contact Lens Anterior Eye* 2007;30:61–6. <https://doi.org/10.1016/j.clae.2006.12.004>.
- [383] Krumeich JH, Kezirian GM. Circular keratotomy to reduce astigmatism and improve vision in stage I and II keratoconus. *J Refract Surg* 2009;25:357–65. <https://doi.org/10.3928/1081597X-20090401-07>.
- [384] Leccisotti A. Effect of circular keratotomy on keratoconus. *J Cataract Refract Surg* 2006;32:2139–41. <https://doi.org/10.1016/j.jcrs.2006.06.040>.

- [385] Sekundo W, Stevens JD. Surgical treatment of keratoconus at the turn of the 20th century. *J Refract Surg* 2001;17:69–73. <https://doi.org/10.3928/1081-597x-20010101-09>.
- [386] Lyra JM, Trindade FC, Lyra D, Bezerra A. Outcomes of radiofrequency in advanced keratoconus. *J Cataract Refract Surg* 2007;33:1288–95. <https://doi.org/10.1016/j.jcrs.2007.03.042>.
- [387] Alió JL, Claramonte PJ, Cáliz A, Ramzy MI. Corneal modeling of keratoconus by conductive keratoplasty. *J Cataract Refract Surg* 2005;31:190–7. <https://doi.org/10.1016/j.jcrs.2004.10.042>.
- [388] Hycl J, Janek M, Valešová L, Růžička P, Donát A, Kuhnová G, et al. Experimental correction of irregular astigmatism in patients with keratoconus using diode laser thermal keratoplasty. *Ces a Slov Oftalmol* 2003;59:382–91.
- [389] Aquavella JV, Smith RS, Shaw EL. Alterations in corneal morphology following thermokeratoplasty. *Arch Ophthalmol* 1976;94:2082–5. <https://doi.org/10.1001/archoph.1976.03910040742008>.
- [390] Colin J, Velou S. Implantation of Intacs and a refractive intraocular lens to correct keratoconus. *J Cataract Refract Surg* 2003;29:832–4. [https://doi.org/10.1016/S0886-3350\(02\)01618-8](https://doi.org/10.1016/S0886-3350(02)01618-8).
- [391] El-Raggal TM, Abdel Fattah AA. Sequential Intacs and Verisyse phakic intraocular lens for refractive improvement in keratoconic eyes. *J Cataract Refract Surg* 2007;33:966–70. <https://doi.org/10.1016/j.jcrs.2007.02.024>.
- [392] Coskunseven E, Onder M, Kymionis GD, Diakonis VF, Arslan E, Tsiklis N, et al. Combined intacs and posterior chamber toric implantable collamer lens implantation for keratoconic patients with extreme myopia. *Am J Ophthalmol* 2007;144:387–9. <https://doi.org/10.1016/j.ajo.2007.05.035>.
- [393] Vincent SJ, Fadel D. Optical considerations for scleral contact lenses: A review. *Cont Lens Anterior Eye* 2019;42:598–613. <https://doi.org/10.1016/j.clae.2019.04.012>.
- [394] Konda S, Ambati BK. Intracorneal ring segments followed by toric pseudoaccommodating IOL for treatment of patients with corneal ectasia and cataract. *Am J Ophthalmol Case Reports* 2020;18. <https://doi.org/10.1016/j.ajoc.2020.100693>.
- [395] Mounir A, Mostafa EM. Combined accelerated corneal collagen crosslinking and intrastromal Kerarings implantation for treatment of advanced superior keratoconus. *GMS Ophthalmol Cases* 2020;10. <https://doi.org/10.3205/oc000137>.
- [396] Gore DM, Leucci MT, Anand V, Fernandez-Vega Cueto L, Arba Mosquera S, Allan BD. Combined wavefront-guided transepithelial photorefractive keratectomy and corneal crosslinking for visual rehabilitation in moderate keratoconus. *J Cataract Refract Surg* 2018;44:571–80. <https://doi.org/10.1016/j.jcrs.2018.03.026>.
- [397] Gadhvi KA, Romano V, Fernández-Vega Cueto L, Aiello F, Day AC, Allan BD. Deep anterior lamellar keratoplasty for keratoconus: Multisurgeon results. *Am J Ophthalmol* 2019;201:54–62. <https://doi.org/10.1016/j.ajo.2019.01.022>.
- [398] Arnalich-Montiel F, Alió del Barrio JL, Alió JL. Corneal surgery in keratoconus: which type, which technique, which outcomes? *Eye Vis* 2016;3:2. doi: 10.1186/s40662-016-0033-y.
- [399] Maya Tong C, Van Dijk K, Melles GRJ. Update on Bowman layer transplantation. *Curr Opin Ophthalmol* 2019;30:249–55. <https://doi.org/10.1097/ICU.0000000000000570>.
- [400] Dapena I, Parker JS, Melles GRJ. Potential benefits of modified corneal tissue grafts for keratoconus: Bowman layer “inlay” and “onlay” transplantation, and allogenic tissue ring segments. *Curr Opin Ophthalmol* 2020;31:276–83. <https://doi.org/10.1097/ICU.0000000000000665>.
- [401] El ZM, Del BJ, Arnalich-Montiel F, De Miguel MP, Makdissy N, Alió JL. Corneal stroma regeneration: New approach for the treatment of cornea disease. *Asia-Pacific J Ophthalmol* 2020;9:571–9. <https://doi.org/10.1097/APO.0000000000000337>.
- [402] Alió del Barrio JL, Arnalich-Montiel F, De Miguel MP, El Zarif M, Alió JL. Corneal stroma regeneration: Preclinical studies. *Exp Eye Res* 2021. <https://doi.org/10.1016/j.exer.2020.108314>.
- [403] Brierly SC, Izquierdo L, Mannis MJ. Penetrating keratoplasty for keratoconus. *Cornea* 2000;19:329–32. <https://doi.org/10.1097/00003226-200005000-00014>.
- [404] Sray WA, Cohen EJ, Rapuano CJ, Laibson PR. Factors associated with the need for penetrating keratoplasty in keratoconus. *Cornea* 2002;21:784–6. <https://doi.org/10.1097/00003226-200211000-00011>.
- [405] Watson SL, Ramsay A, Dart JKG, Bunce C, Craig E. Comparison of deep lamellar keratoplasty and penetrating keratoplasty in patients with keratoconus. *Ophthalmology* 2004;111:1676–82. <https://doi.org/10.1016/j.ophtha.2004.02.010>.
- [406] Keane M, Coster D, Ziaei M, Williams K. Deep anterior lamellar keratoplasty versus penetrating keratoplasty for treating keratoconus. *Cochrane Database Syst Rev* 2014:CD009700. <https://doi.org/10.1002/14651858.CD009700.pub2>.
- [407] Gordon MO, Steger-May K, Szczotka-Flynn L, Riley C, Joslin CE, Weissman BA, et al. Baseline factors predictive of incident penetrating keratoplasty in keratoconus. *Am J Ophthalmol* 2006;142:923–30. <https://doi.org/10.1016/j.ajo.2006.07.026>.
- [408] Sabater-Cruz N, Figueras-Roca M, Padró-Pitarch L, Tort J, Casaroli-Marano RP. Corneal transplantation activity in Catalonia, Spain, from 2011 to 2018: Evolution of indications and surgical techniques. *PLoS ONE* 2021;16:e0249946. <https://doi.org/10.1371/journal.pone.0249946>.
- [409] Melles GRJ, Lander F, Rietveld FJR, Remeijer L, Beekhuis WH, Binder PS. A new surgical technique for deep stromal, anterior lamellar keratoplasty. *Br J Ophthalmol* 1999;83:327–33. <https://doi.org/10.1136/bjo.83.3.327>.
- [410] Ang M, Mehta JS. Deep anterior lamellar keratoplasty as an alternative to penetrating keratoplasty. *Ophthalmology* 2011;118:2306–7. <https://doi.org/10.1016/j.ophtha.2011.07.025>.
- [411] Hauk L. Corneal transplantation. *AORN J* 2018;107:P11–4. <https://doi.org/10.1002/aorn.12079>.